

Studies on the Reproduction of Japanese Smooth Dogfishes,
Mustelus manazo and *M. griseus* *

By

Kazuyuki TESHIMA

Contents

Introduction	115
Acknowledgements	115
1. Materials and Methods	115
2. The Female	119
2.1. The ovary and oogenesis	119
2.1.1. The ovary	119
2.1.2. Oogenesis	120
2.1.3. Relationship between development of ova and growth of embryos	122
2.1.4. Degeneration and absorption of ova in the ovary	122
2.1.5. The follicle after ovulation	123
2.1.6. Consideration	123
2.2. The oviduct	126
Consideration	127
2.3. The nidamental gland	129
Consideration	131
2.4. The uterus	131
Consideration	133
2.5. The uterine compartment	135
Consideration	137
2.6. The embryo	137
2.6.1. Embryonic growth and yolk absorption	137
2.6.2. Relationship between adult length and the number of embryos per litter	141
2.6.3. Consideration	143

* Contribution from Shimonoseki University of Fisheries, No. 884. Received July 28, 1980.
A dissertation submitted to Faculty of Agriculture, Kyoto University, Kyoto, in partial fulfillment of the requirements for the degree of Doctor of Agriculture, 1980.

2.7.	The placenta	144
2.7.1.	Establishment of the placenta	144
2.7.2.	Histology of the placenta	145
2.7.3.	Consideration	147
2.8.	The yolk stalk	150
2.8.1.	Structure of yolk stalk	150
2.8.2.	Epithelium of ductus vitellointestinalis	152
2.8.3.	Consideration	154
2.9.	Maturity	154
	Consideration	155
3.	The Male	155
3.1.	The testis and spermatogenesis	155
3.1.1.	The testis	155
3.1.2.	Spermatogenesis	155
3.1.3.	Monthly change of the gonad index and spermatogenic cells	157
3.1.4.	Consideration	161
3.2.	The spermiduct	164
3.2.1.	Epididymis	164
3.2.2.	Spermiduct	165
3.2.3.	Seminal vesicle	165
3.2.4.	Consideration	167
3.3.	The clasper	169
3.3.1.	Pelvic fin and clasper skeleton	169
3.3.2.	Clasper action	171
3.3.3.	Consideration	173
3.4.	The siphon sac	176
	Consideration	179
3.5.	Maturity	179
3.5.1.	Relationship between the clasper length and total length	179
3.5.2.	Relationship between the testis weight and total length	181
3.5.3.	Consideration	181
4.	Taxonomy of Japanese <i>Mustelus</i> species	182
4.1.	Japanese species of the genus <i>Mustelus</i>	183
4.2.	Reproductive structure as taxonomic criteris	185
4.2.1.	Female	185
4.2.2.	Male	185
4.3.	Taxonomy	185
5.	General Consideration	185
6.	Summary	193
	References	194

Introduction

Mustelus manazo BLEEKER and *M. griseus* PIETSCHMANN are two of the most common species in the coastal waters of Japan. They live near the bottom of the sea between 50 and 100m in depth, and are very sluggish species. Usually the mature male and female are less than 1,000mm in total length. Teeth of both jaws, unlike those of the other species, are low and rounded and show the mosaic arrangement. Both jaws are so strong that they can eat mollusks with hard shells without difficulty and the smashed shells are often found in their stomachs.

Both species are landed at the fish markets in Shimonoseki and Nagasaki regions throughout the year so that they provide most suitable material for reproductive cycle investigations. Also, these sharks have an important role as food in these regions.

Because the external characters of *Mustelus manazo* and *M. griseus* closely resemble each other (Fig. 1), it is not easy to distinguish between them. Investigation of their reproduction has, however, made clear that there are some important differences between the two species. In the female, the author has studied the ovary, oogenesis, oviduct, nidamental gland, uterus, placenta and embryo; in the male; the testis, spermatogenesis, spermiduct, seminal vesicle, and clasper were investigated and compared.

Acknowledgments


The author wishes to express his sincere appreciation to Professor Tamotsu IWAI of Kyoto University for his invaluable suggestions and criticism in carrying out this work. Thanks are extended to Professor Shigeyuki KOGA, Professor Kei NAKASAI and Dr. Akira TAKEMURA of

Nagasaki University for their continued interest and encouragement, and also to Dr. Perry W. GILBERT of Mote Marine Laboratory, Florida, USA and Dr. Daniel J. SHEEHY of University of Rhode Island, Rhode Island, USA for their kindness in reviewing and correcting the English manuscript. Finally, the author wishes to express his sincere gratitude to Professor Kazuhiro MIZUE of Ocean Research Institute, University of Tokyo, who originally suggested this topic, for his advice and encouragement throughout the course of this study.

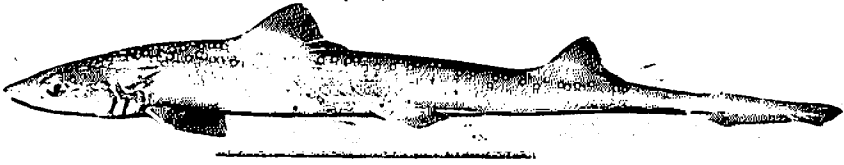
1. Materials and Methods

The materials upon which the present investigation was carried out are *Mustelus manazo* BLEEKER (Fig. 1A, B, C, D) and *M. griseus* PIETSCHMANN (Fig. 1E, F). The number of specimens, total length and date collected are listed in Table 1 and 2. The total number of specimens was 528. Of these, 434 were collected at the fish market in Shimonoseki; These specimens were caught by bull trawlers in the East China Sea. The 93 specimens were collected at the fish market in Nagasaki, and these were caught by bottom long liners in the northern waters of the East China Sea. The remaining specimen, caught by the bottom long liners in the waters off Yoshimo, was collected alive at the fish market in Yoshimo near Shimonoseki, Japan.


Gonads removed from the specimens were fixed in 10percent formalin. Paraffin sections were made of the ovaries, oviducts, nidamental glands, uteri, placentae, yolk stalks, testes, epididymides, spermiducts, siphon sacs and seminal vesicles. Sections were cut at 4–10 μ m, and stained with hanzen's haematoxylin and eosin. The yolk stalk of the specimen collected at Yoshimo was examined by the



A




B




C



D



E



F

Table 1. Total length and the number of *Mustelus manazo* specimens used in the present investigation.

Date collected	Male		Female	
	No. of specimens	Total length (mm)	No. of specimens	Total length (mm)
1972 May	—	—	2	610—650
June	1	550	2	695—705
July	1	625	2	560—595
Aug.	1	648	6	635—810
Sept.	1	615	14	675—848
Oct.	—	—	13	747—1174
1974 Jan.	—	—	1	908
Mar.	—	—	10	712—776
1975 May	2	709—717	—	—
July	14	507—693	4	644—787
Aug.	20	544—677	—	—
Sept.	21	496—671	4	564—668
Oct.	16	652—825	—	—
Nov.	11	646—970	2	770—825
Dec.	7	652—736	—	—
1976 Jan.	4	710—753	—	—
Feb.	10	477—762	22	494—725
Mar.	12	450—1010	19	475—701
Apr.	18	638—728	8	580—994
May	17	683—831	1	721
1971 Apr.*	8	520—690	20	540—940
May*	18	575—710	10	615—845
June*	15	470—656	7	494—590
July*	13	435—650	—	—
Aug.*	—	—	2	830—890
Total	210	450—1010	149	475—1174

*Specimens collected at the fish market in Nagasaki, Japan.

Fig. 1. Specimens used in the present investigation.

- A. Female *Mustelus manazo* BLEEKER with distinct white spots.
- B. Male *M. manazo* with distinct white spots.
- C. Female *M. manazo* with indistinct white spots.
- D. Male *M. manazo* with indistinct white spots.
- E. Female *M. griseus* PIETSCHMANN.
- F. Male *M. griseus*.

electron microscope.

The placentae used for the histological examination were found in the uteri of the females whose embryos ranged from 89 to 294 mm in total length (Table 3). These placentae showed varying degrees of development, from the commencement of placentation to a definitive placenta.

In order to examine the monthly

change of spermatogenic cells throughout the year, histological sections were made of all the testes collected.

Pelvic fins and claspers were dissected to examine their skeletal elements, and at the same time, they were stained with alizarin red S to examine the formation and growth of the skeletal elements.

Table 2. Total length and the number of *Mustelus grisesus* specimens used in the present investigation.

Date collected	Male		Female	
	No. of specimens	Total length (mm)	No. of specimens	Total length (mm)
1972 June	4	750-760	1	675
July	1	680	3	760-880
Aug.	4	672-797	4	835-967
Sept.	1	770	—	—
Oct.	7	763-912	7	858-959
1973 Jan.	—	—	1	868
Mar.	—	—	5	934-1079
1974 May	7	732-813	—	—
June	10	615-772	—	—
July	11	638-790	—	—
Aug.	18	568-783	—	—
Sept.	6	726-758	—	—
Oct.	7	660-758	—	—
Nov.	10	710-827	—	—
1975 Jan.	6	791-909	—	—
Feb.	11	752-888	—	—
Mar.	2	820-870	—	—
Apr.	5	720-872	—	—
May	17	712-814	—	—
July	2	668-728	3	761-808
1976 Jan.	11	578-870	1	564
Apr.	—	—	3	915-1079
1975 Sept.**	—	—	1	1042
Total	140	568-912	29	675-1079

**Specimen collected at the fish market in Yoshimo near Shimonoseki.

Table 3. The placentae used for the histological examination were taken out from the females whose embryos ranged from 89 to 294 mm in total length.

Date collected	Total length of adults	No. of embryos	Total length of embryos
October 3, 1972	858 mm	7	89–100mm
October 3, 1972	890mm	7	93–104mm
October 3, 1972	901 mm	7	112–124mm
October 31, 1972	945 mm	6	140–157mm
January 30, 1973	868 mm	6	235–237mm
March 31, 1973	1010 mm	5	238–252mm
March 31, 1973	978 mm	8	272–294mm
March 31, 1973	934 mm	5	268–282mm

2. The Female

The female reproductive organs in *Mustelus manazo* and *M. griseus* are composed of the ovary, the oviduct, the nidamental gland and the uterus (Fig. 2). Oocytes ovulated from the ovary are received through the common ostium where they are distributed to both oviducts. The eggs, fertilized in the oviduct or in the nidamental gland, descend into the uterus where they develop into embryos.

2.1. The ovary and oogenesis

2.1.1. The ovary

In both *Mustelus manazo* and *M. griseus* the ovary is formed at the anterior end of the epigonal organ. The epigonal organ shows the same histology in both sexes; the epigonal organ consists of granule cells among which there are many capillaries (Fig. 3A, Fig. 20A). The epigonal organ in both species are small in size when the shark is immature. Although the epigonal organ increases in size with growth of the shark, the left epigonal organ becomes rudimentary, and only the right one continues to grow. The ovary is formed at the anterior end of the right epigonal

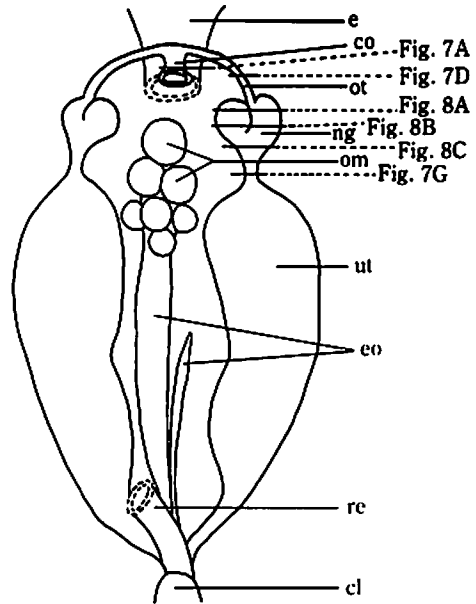


Fig. 2. Female reproductive organs in *Mustelus manazo* and *M. griseus*.

cl: cloaca, co: common ostium, e: esophagus, eo: epigonal organ, ng: nidamental gland, om: ovum, ot: oviduct, re: rectum, ut: uterus.

organ. Only the right ovary is thus functional in *M. manazo* and *M. griseus* (Fig. 2).

The external surface of the ovary is covered with a simple epithelium of cuboidal or columnar cells. Oocytes at different sizes are seen in the ovary. The oocyte is surrounded by the follicular epithelial cells (Fig. 3B). In both *Mustelus manazo* and *M. griscus*, the follicle is made up of the ooplasm, zona radiata, vitelline membrane and follicular epithelium (Fig. 3E). The structure of the follicle changes as the oocyte develops.

2.1.2 Oogenesis

The same process is observed in the oogenesis in *Mustelus manazo* and *M. griscus*.

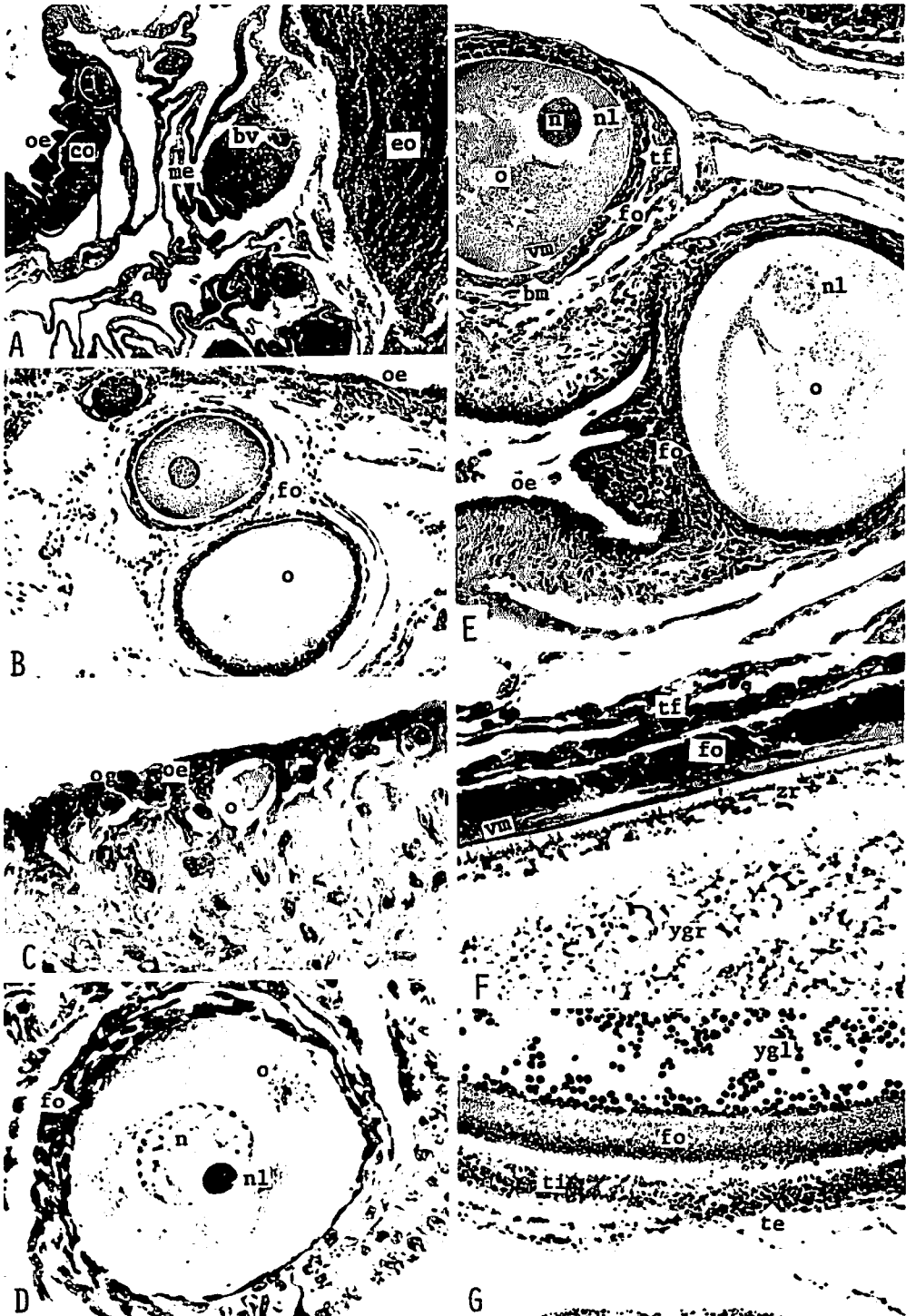
The ovarian cortex is formed at the anterior end of the right epigonal organ as the shark reaches maturity. The reproductive cells appear in the ovarian epithelium (Fig. 3C) and sink into the ovarian cortex. The oocyte, at early developmental stage (15–20 μ m in diameter), is covered with two to three squamous cells (Fig. 3C). When the oocyte has reached the diameter of about 130 μ m, the oocyte becomes covered with

a single layer of squamous cells. A large nucleolus is situated peripherally in the nucleus and part of the chromatin is well stained with haematoxylin (Fig. 3D). When the oocyte is about 350 μ m in diameter, the follicular epithelium changes from a simple squamous epithelium to a simple cuboidal epithelium. At this stage, the nucleolus divides into segments and these small nucleoli are arranged along the nuclear membrane. At the same time, the vitelline membrane and zona radiata become visible. External to the follicular epithelium, the theca folliculi is already formed by the two to three layers of cells of connective tissue. The follicular epithelium is bounded on the theca folliculi, by the basement membrane (Fig. 3E). When the oocyte develops up to about 2mm in diameter, the follicular epithelium changes from a simple cuboidal epithelium to a simple columnar epithelium. At this stage, yolk granules begin to develop into yolk globules and the zona radiata is clearly visible. In the zona radiata, many vertical stripes become visible (Fig. 3F). After this stage, the oocyte gradually

Fig. 3. Development of oocytes in *Mustelus manazo* and *M. griscus*.

- A. The ovary is formed at the anterior end of the epigonal organ. *M. manazo*, $\times 20$.
- B. The ovary contains oocytes at various developmental stages. The oocyte is covered with the follicular epithelium. *M. griscus*, $\times 50$.
- C. Oogonia in the ovarian epithelium. The oocyte at early developmental stage is covered with two to three squamous cells. *M. manazo*, $\times 200$.
- D. The oocyte is covered with a simple squamous epithelium. A large nucleolus is situated peripherally in the nucleus, and part of the chromatin is well stained with haematoxylin. *M. griscus*, $\times 200$.
- E. The vitelline membrane and the zona radiata are observed when the follicular epithelium changes from a simple squamous to a simple cuboidal epithelium. The oocyte in the left is lined by the simple cuboidal epithelium. At this stage, the nucleolus divides into segments in the nucleus. *M. manazo*, $\times 50$.
- F. The zona radiata is clearly visible. The yolk granules begin to develop into yolk globules when the follicular epithelium changes from the simple cuboidal to the simple columnar epithelium. *M. manazo*, $\times 20$.
- G. A mature oocyte. The follicular epithelium consists of the stratified epithelium. The theca interna and the theca externa are observed. *M. manazo*, $\times 50$.

bm: basement membrane, bv: blood vessel, co: cortex, eo: epigonal organ, fo: follicular epithelium, me: medulla, n: nucleus, nl: nucleolus, o: oocyte, og: oogonium, oe: ovarian epithelium, tf: theca folliculi, te: theca externa, ti: theca interna, vm: vitelline membrane, zr: zona radiata, ygl: yolk globules, ygr: yolk granules.



increases in size. The follicular epithelium of the oocyte developed more than 10mm in diameter consists of stratified layers of cells. The internal layer therefore consists of a single layer of tall columnar cells, and external to this are two to three layers of cuboidal cells. The theca folliculi becomes differentiated into two layers and the internal layer is slightly stained with eosin (Fig. 3C). At this stage, the zone radiata becomes invisible, and the vitelline membrane is no longer clear. The cytoplasm is filled with yolk globules which are well stained with eosin. Oocytes continue to develop and then protrude at the surface of the ovary. Ovulation occurs when the oocyte has reached the diameter of about 20mm in *M. manazo* and about 15mm in *M. griseus*.

2.1.3. Relationship between development of ova and growth of embryos

Since the description of the growth of embryos will be made later, this paragraph will deal only with the development of ova.

Relationship between the monthly average of the total length of the largest embryos in both uteri and the monthly average of the diameter of the largest ova is shown in Fig. 4. Fig. 5 indicates the relationship between the total length of the largest embryo in both uteri and the diameter of the largest ovum in the adult.

In both *Mustelus manazo* and *M. griseus*, the diameter of ovum reaches a maximum in July, and a minimum in August. After September the ovum increases in diameter with the embryonic development, and again reaches the maximum diameter during next July. The mature oocyte reaches the diameter of about 20mm in *M. manazo*, and 15mm in *M. griseus*. From the facts described here it is expected to estimate the reproductive season including the ovulation, mating and fertilization.

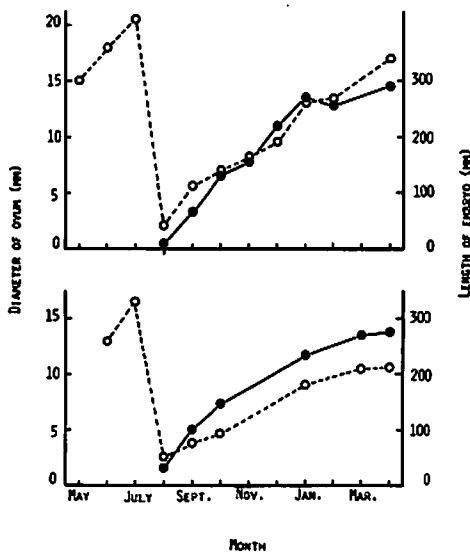


Fig. 4. Relationship between growth of embryo (closed circle) and development of ova (open circle) by month in *Mustelus manazo* (upper) and *M. griseus* (lower).

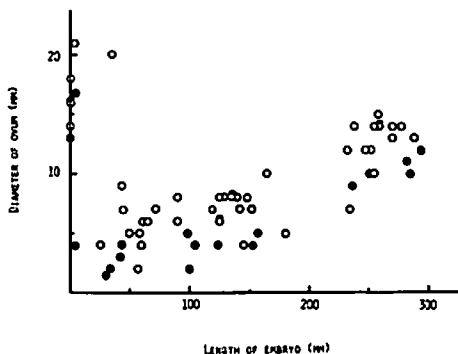


Fig. 5. Relationship between embryo length and ovum diameter in *Mustelus manazo* (open circle) and *M. griseus* (closed circle).

2.1.4. Degeneration and absorption of the ova in the ovary

Although relatively a large number of oocytes appear in the ovary, the number of eggs ovulated in an ovulating season is only four to eight in *Mustelus manazo* and

six to ten in *M. griseus*. Most oocytes which appear in the ovary thus do not reach the maturity and they degenerate and are absorbed during the course of development.

The process of degeneration and absorption of oocytes is divided into two time segments; 1) The degeneration and absorption of oocytes which occur early in the developmental process and 2) those which occur relatively later in the developmental process. The first disintegration and absorption occur before the oocytes reach the diameter of about $150\mu\text{m}$ (Fig. 6A). A very large number of oocytes disappear during the first disintegration and absorption. The oocytes which have survived develop up to 3 to 4mm in diameter. At this stage, the yolk globules are already formed. Then, the second disintegration and absorption take place (Fig. 6B) and only the oocytes expected to be ovulated are remained. During the second degeneration, the follicular epithelium of the oocyte becomes thicker and multilayered. The follicular epithelial folds invade the cytoplasm. The follicular epithelium consists of large cells, and it is distinguishable from the theca folliculi by the basement membrane. Two layers are observed in the theca folliculi (Fig. 6B).

2.1.5. The follicle after ovulation

In the follicle immediately after ovulation (Fig. 6C—lower follicle, D), the follicular epithelium and the theca folliculi, composed of two, inner and outer, layers are observed. The follicular epithelium becomes thicker and consists of spherical polygonal cells. Capillaries are scattered in the boundary between the follicular epithelium and theca folliculi. The theca interna of the theca folliculi is well stained with eosin and is composed of the small-sized cells. The cells composing the theca

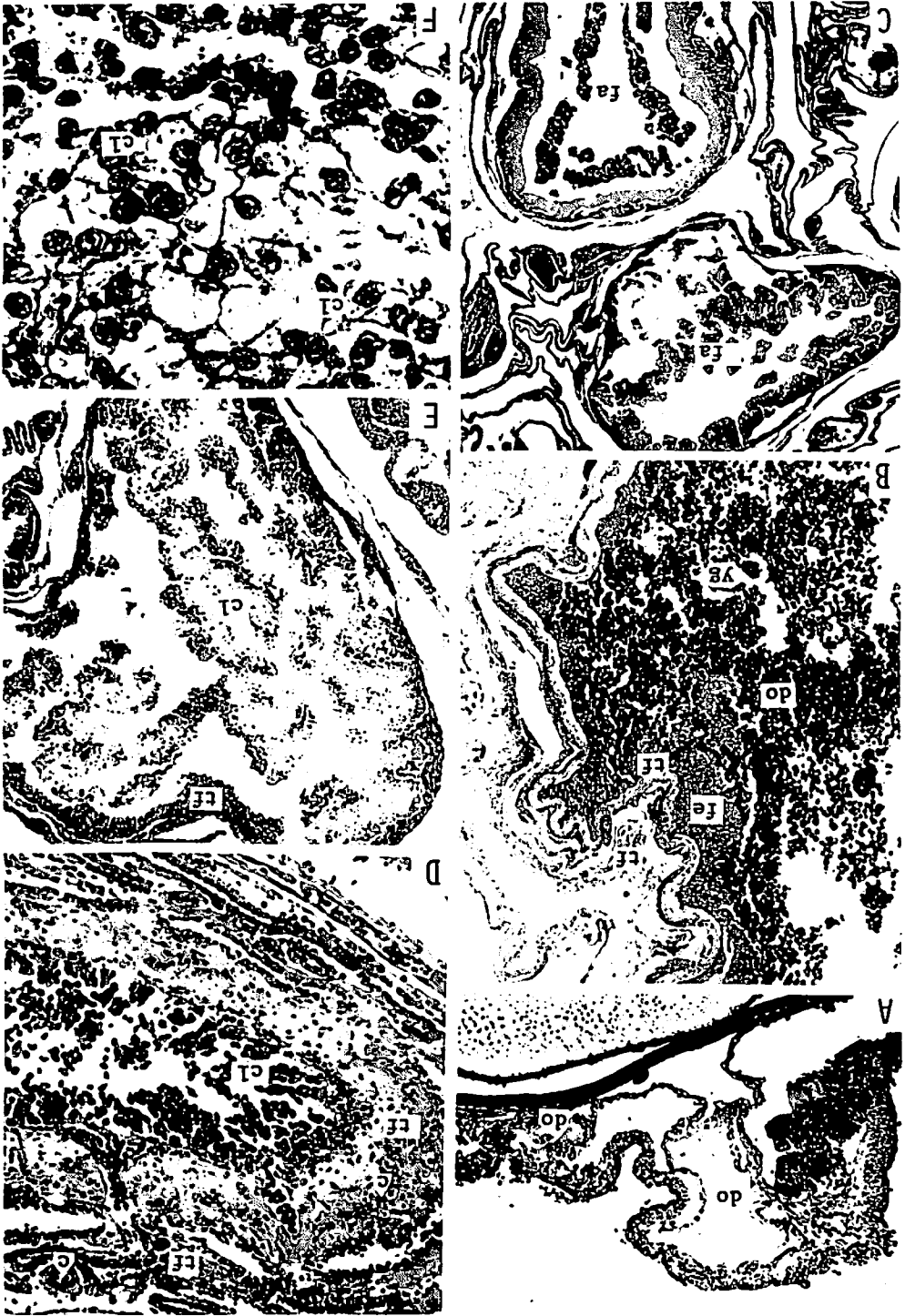
externa are similar in shape to those of the follicular epithelium, and the capillaries are scattered in the theca externa. The cells of the theca externa are connected with those of the follicular epithelium in some areas through the theca interna.

In the follicle, a short period after ovulation (Fig. 6C—upper follicle, E), the follicular epithelium and the theca folliculi are observed. The theca folliculi becomes much thinner and only a single layer is recognizable. The cells of the theca folliculi are similar to those of the theca externa immediately after ovulation. The follicular epithelial cells become much larger compared to those immediately after ovulation. The cytoplasm, in particular, are larger (Fig. 6F).

2.1.6 Consideration

Only one ovary is functional in *Mustelus manazo* and *M. griseus*. The ovary is thus formed at the anterior end of the right epigonal organ. In many species of sharks, only one ovary is usually formed. It has been shown, however, that both right and left ovaries are functional in some species such as *Scoliodon* and *Squalus* species.^{1~5)}

The structure of the oocyte and the process of the oogenesis in *Mustelus manazo* and *M. griseus* are similar to *Rhinobatus granulatus*⁶⁾ and *Cetorhinus maximus*⁷⁾. In these sharks, as the oocyte develops, the follicular epithelium changes from a simple squamous epithelium to a simple cuboidal epithelium, to a simple columnar epithelium and finally to a stratified epithelium. The connective tissue surrounding the follicular epithelium becomes the theca folliculi. With further development of oocyte, the theca folliculi are differentiated into two layers, the theca interna and the theca externa. The process observed in the oogenesis of the selachian appears to be more similar to



that in the mammalian rather than in the teleost. In the selachian, however, the antrum folliculi is not formed. According to YAMAMOTO⁹⁾ and MIZUE^{9,10)}, the follicular epithelium in the teleost is usually thinner than that in the selachian.

That corpora lutea are formed in the follicles where ovulation occurred has been reported and discussed by scientists such as WALLACE¹¹⁾, working with *Spinax niger*, SAMUEL⁶⁾, with *Rhinobatus granulatus*, HISAW and ALBERT¹²⁾, with *Squalus acanthias*, HISAW and HISAW¹³⁾, with six species of elasmobranch, MATTHEWS⁷⁾, with *Cetorhinus maximus* and TEWINKEL¹⁴⁾, with *Mustelus canis*. In *M. manazo* and *M. griseus*, the cells similar to lutein cells are observed. These cells are shown in Fig. 6F. The cells in the internal layer of the follicle, where the ovulation has occurred, are spherical polygonal in shape. These cells have large-sized cytoplasm where substances like the secretory granules appear to exist. In the follicle after ovulation, the section where these large cells are situated is in accord with that where the follicular epithelial cells of the follicle are situated before ovulation. In addition to these facts, the specimens contained the fertilized eggs in uteri. These facts suggest that the large cells in the follicle after ovulation are histologically similar to the lutein cells in mammalian, i.e., these cells are morphologically similar to the lutein cells composing the corpus

luteum graviditatis found in the northern fur seal.^{15,16)} Moreover, these cells in *M. manazo* and *M. griseus* closely resemble the lutein cells defined by those scientists described above. TESHIMA et al.¹⁷⁾, working with the oogenesis in the selachian, described that the cells similar to lutein cells were not observed. The present investigation has, however, proved that the cells similar to lutein cells do exist.

In the present specimens investigated the follicular epithelial cells in the large degenerating oocyte were similar, in morphology, to lutein cell-like cells of the follicle immediately after ovulation. It seems to be therefore impossible in the present investigation to distinguish the degenerating oocyte where all the yolk globules are absorbed from the follicle following ovulation. HISAW and HISAW¹³⁾ indicated that it is impossible to distinguish between atresia of the large follicle and the corpus luteum formed following ovulation because the reaction of the granulosa under the two situations seems identical. MATTHEWS⁷⁾ described that the degenerating oocyte has a clear structureless membrane resembling the vitelline membrane inside the follicular epithelium. He therefore distinguished the corpus luteum formed by ovulation from the atretic corpus luteum by this membrane. LANCE and CALLARD¹⁸⁾, working with corpora lutea of *Squalus acanthias*, mentioned that the atretic follicles at late stage could not be dis-

Fig. 6. Degenerating oocytes and follicles after ovulation in *Mustelus manazo* and *M. griseus*.

- A. Degenerating oocyte at its early developmental stage. *M. griseus*, ×50.
- B. Degenerating oocyte at its late developmental stage. *M. manazo*, ×20
- C. The follicle immediately after ovulation (lower) and the follicle a short period after ovulation (upper). *M. manazo*, ×10.
- D. The follicle immediately after ovulation. The follicular epithelium becomes thicker and consists of spherical polygonal cells. *M. griseus*, ×50.
- E. The follicle a short period after ovulation. The follicular epithelial cells increase in number and occupy the inside of the follicle. *M. manazo*, ×50.
- F. A partial magnification of E. The cytoplasm of each follicular epithelial cell becomes larger and appears to contain the secretory granules-like substances. *M. manazo*, ×200.

c: capillary, cl: lutein cell-like cell, do: degenerating oocyte, fa: follicle after ovulation, fe: follicular epithelium, tf: theca folliculi, yg: yolk globules.

tinguished histologically from the corpus luteum formed by the post-ovulatory follicle. They, however, found that 3β -HSD (S beta hydroxysteroid dehydrogenase) activity is present in corpora lutea derived from post-ovulatory follicles though the corpora lutea derived from atretic follicles never, at any time, show 3β -HSD activity in *S. acanthias*. TEWINKEL¹⁴⁾ histochemically discussed corpora lutea in *Mustelus canis* purporting that a strong indication of steroidogenesis is seen in the yolky atretic follicles at late stages, while the granulosa of the post-ovulatory follicles are constantly negative in steroid reaction except for a very few cases.

WALLACE¹¹⁾ recognized old corpora lutea, which are about one year old, in the ovary of *Spinax niger*. At the same time, he found the nearly full-termed embryos in uteri of the same specimens. HISAW and ALBERT¹²⁾ observed the corpora lutea which were about 18 to 20 months old, while they found developing oocytes in the same ovary. Usually, in the selachian, the oocytes develop with the embryonic development and they reach maturity before the embryos are born.^{4,19~22)} One of the functions of the corpus luteum graviditatis in mammalian is to restrain the following ovulation. If the function of the corpus luteum in the selachian is the same as that in the mammalian, it would be unexpected that both the corpus luteum and the developing oocytes exist in the same ovary as was observed in *Spinax niger* and *Squalus acanthias*. Moreover, it is necessary for the selachian that the oocytes develop for the following ovulation immediately after the ovulation.^{20,21)} It would not be thus expected in the selachian for the corpus luteum to exist for a long time after ovulation as has been suggested in *Spinax niger* and *Squalus acanthias*.

In *Mustelus manazo* and *M. griseus* the cells similar to lutein cells were not found

in the ovaries of females which contained embryos. It may be therefore considered that the lutein cell-like cells, formed in the follicle after ovulation, degenerate and disappear within a short period of time in *M. manazo* and *M. griseus*.

The function of the corpus luteum in the selachian appears to be different from that in the mammalian. It is necessary to investigate the corpus luteum in the selachian histochemically and endocrinologically.

In both *Mustelus manazo* and *M. griseus* the diameter of oocyte reaches a maximum in July, and a minimum in August. The fertilized eggs and small-sized embryos are found in uteri of both species in July and August. These facts suggest that ovulation should occur during the period from June to August. The ovulating season agrees with the mating season in male as will be described later. In *M. manazo* and *M. griseus* the ovulation, mating and fertilization thus take place during the period from June to August.

KUDO²³⁾, working with *Mustelus manazo* occurring in Bungo Suido and Iyo Nada (waters surrounded by Honshu, Kyushu and Shikoku, Japan), and TESHIMA et al.²⁴⁾, with *M. manazo* in the northern waters of the East China Sea, described that ovulation, mating and fertilization occur in June and July, respectively in both waters. According to HISAW and ABRAMOWITZ^{25,26)}, in *M. canis* occurring in waters off the northeastern coast of the United States, ovulation and fertilization take place in late June and early July.

2.2. The oviduct

The ovulated eggs are received through a common ostium and distributed to both oviducts. The funnellform common ostium is formed by fusion of the anterior ends of both oviducts which lie along the

esophagus. The common ostium protrudes toward the ovary for 5–6mm. The ostium lies in the falciform ligament, and the diameter at the opening is about 5–6mm. Leading from the ostium, the oviduct extends posteriorly for about 30 to 40 mm and is continuous with the nidamental gland. The remainder of the oviduct is situated between the nidamental gland and the uterus. In the late stage of gestation, this portion of the oviduct becomes very short due to the great expansion of the uterus.

Both *Mustelus manazo* and *M. griseus* show the same histological structure in the oviduct.

The mucous membrane of the ostium has many longitudinal folds. The internal surface of the lumen is lined by a single layer of tall ciliated columnar cells. Some of folds are covered with the stratified epithelium at their bases. These epithelial cells have a large amount of cytoplasm. The basement membrane is not clear and the lamina propria mucosae is thin. External to the lamina propria mucosae are the muscular coat (which comprises the fibrous connective tissue), the smooth muscle fibers and the large-sized blood vessels. The external surface is lined by the simple cuboidal epithelium (Fig. 7A,B).

The internal surface of the oviduct of the immature shark is lined by a single layer of columnar cells. In the connective tissue surrounding the epithelium there are many lymphocytes and blood vessels. The external surface is covered with a single layer of flattened cuboidal cells (Fig. 7C).

The oviduct situated between the common ostium and the nidamental gland (Fig. 7D): Many longitudinal folds, protruding from the wall, occupy the lumen. The epithelium of the mucous membrane consists of a single layer of the tall ciliated columnar cells. The epithelial

cells at the base of folds are much taller than those at the tips (Fig. 7E). The basement membrane is clear and the lamina propria mucosae is composed of the fibrous connective tissue. The muscular coat consists of the irregularly running muscle fibers, the connective tissue and the large-sized blood vessels. The external surface is lined by the simple cuboidal epithelium. The lumen of the oviduct of a single female, collected during the reproductive season, contained spermatozoa (Fig. 7F).

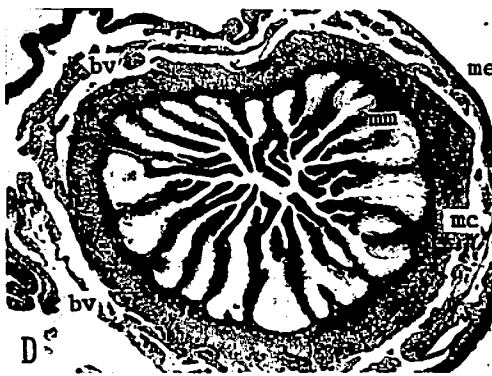
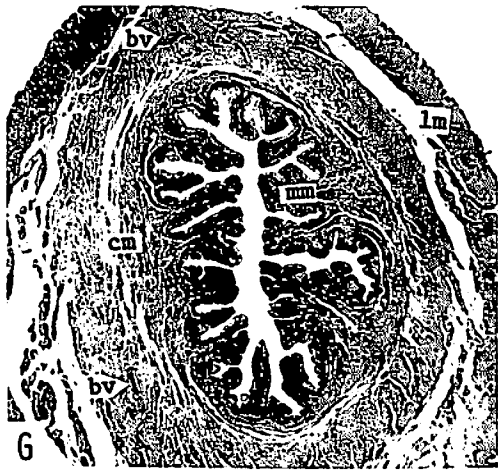
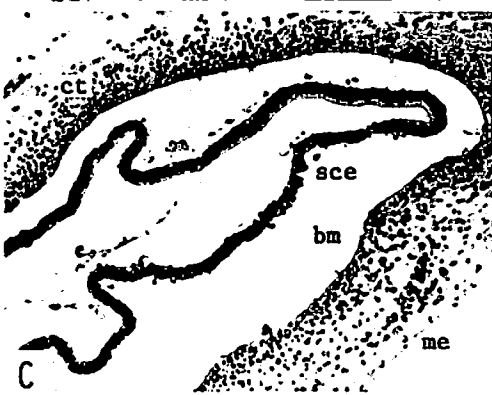
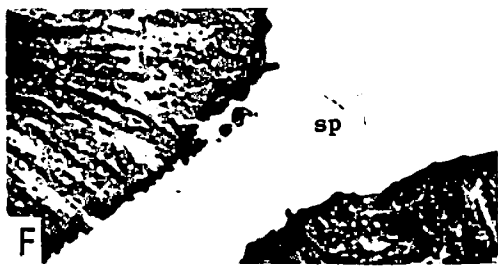
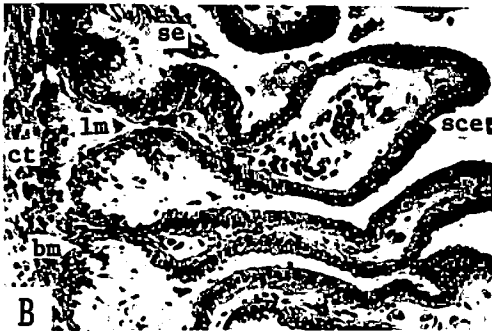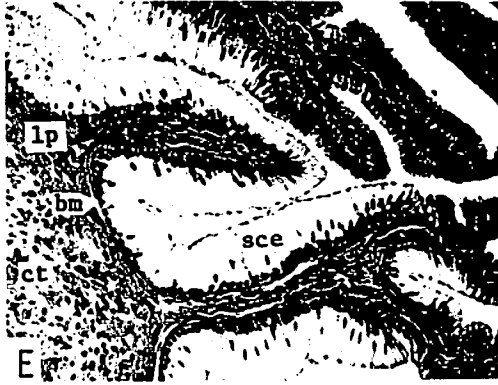
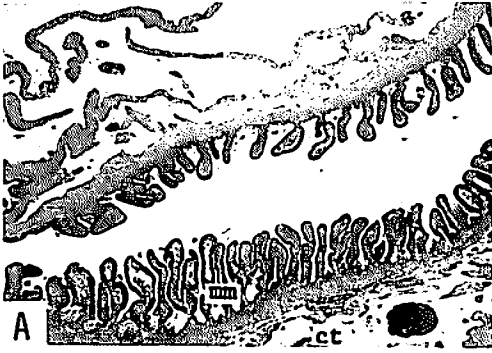
The oviduct extending posteriorly from the nidamental gland (Fig. 7G): The longitudinal folds of the mucous membrane are smaller and shorter than those of the oviduct extending anteriorly from the nidamental gland. The epithelium consists of a single layer of tall ciliated columnar cells (Fig. 7H). The epithelium shows the same thickness throughout. The basement membrane is relatively clear, and the lamina propria mucosae is formed by the fibrous connective tissue. External to the lamina propria mucosae there is a thicker muscular coat which consists mainly of an inner circular layer of smooth muscle fibers and an outer longitudinal layer.

Consideration

In *Mustelus manazo* and *M. griseus*, the oviduct extending both anteriorly and posteriorly from the nidamental gland show the same histology. However, the longitudinal folds in the lower oviduct are smaller than those in the upper, and the muscle layer in the lower oviduct is much more developed compared with that in the upper.

According to MATTHEWS⁷⁾, the structure of the common ostium and oviduct in *Cetorhinus maximus* is similar to that in *Mustelus manazo* and *M. griseus*.

METTEN²⁷⁾, working with *Scylliorhynchus canicula*, indicated that there is no record



of spermatozoa in the narrow upper region of the oviduct. He also suggests that fertilization takes place in the nidamental gland and not in the upper oviduct as previously supposed. The present investigation has, however, found a few spermatozoa in the oviduct between the common ostium and the nidamental gland (Fig. 7F). Although the number of spermatozoa is very small, this finding suggests that spermatozoa may pass upwards through the nidamental gland and that fertilization may occur in the upper portion of the oviduct. This single specimen contained the fertilized eggs in the uteri.

2.3. The nidamental gland

A heart-shaped nidamental gland is situated between the upper and lower portions of the oviduct (Fig. 2). This gland is made up of the mucous membrane, the tubular glands, the connective tissue comprising muscle fibers, and the mesothelium.

In a nidamental gland of an immature individual, the internal surface is lined by a

pseudostratified columnar epithelium. External to the epithelium is the connective tissue containing many lymphocytes and the smooth muscle fibers circulating externally. The epithelium functions as glandular epithelium (Fig. 8D, E).

The histology of the mature nidamental gland is very complicated and is slightly different at its upper, middle, and lower portions. At the upper portion (Fig. 8A) there are three lumens. The central lumen is continuous with the upper portion of the oviduct. The two other lumens are slender and curved. The mucous membrane of each lumen has many folds, the anterior portion of which are forked. The mucous membrane of the central lumen is lined by a pseudostratified epithelium consisting of ciliated columnar cells (Fig. 8F). Many round or slender shaped tubular glands are found external to the lamina propria mucosae. The internal surface of the tubular glands consists of two layers of cells with long cilia (Fig. 8F). Beyond tubular glands is the fibrous connective tissue containing the circular muscle fibers. The wall of two other lumens show the same histology

Fig. 7. The common ostium and the oviduct in *Mustelus manazo* and *M. griseus*.

- A. Transverse section of the common ostium. The mucous membrane has many longitudinal folds. *M. griseus*, $\times 10$.
- B. A partial magnification of A. The folds of the mucous membrane are lined by the single layer of tall ciliated columnar cells. *M. griseus*, $\times 50$.
- C. Transverse section of the oviduct of an immature female. *M. griseus*, $\times 20$.
- D. Transverse section of the oviduct extending anteriorly from the nidamental gland. Many longitudinal folds, which protrude from the wall, occupy the lumen. *M. griseus*, $\times 10$.
- E. A partial magnification of D. The mucous membrane is lined by a single layer of the tall ciliated columnar cells. The epithelial cells at the base of a fold are much taller than those at the tip. *M. griseus*, $\times 50$.
- F. A partial magnification of D. Two spermatozoa are observed. *M. griseus*, $\times 200$.
- G. Transverse section of the oviduct extending posteriorly from the nidamental gland. The longitudinal folds of the mucous membrane are smaller and shorter than those in D. *M. manazo*, $\times 10$.
- H. A partial magnification of G. The epithelium consists of the single layer of tall columnar cells and it shows the same thickness throughout. *M. manazo*, $\times 50$.

bm: basement membrane, bv: blood vessel, cm: circular muscle fibers, ct: connective tissue, lp: lamina propria mucosae, lm: longitudinal muscle fibers, me: mesothelium, mm: mucous membrane, mc: muscular coat, sce: simple columnar epithelium, sp: spermatozoon, se: stratified epithelium.

as that of the central lumen. In these, the tubular glands are, however, longer than those of the central lumen. Some of the tubular glands near the mucous membrane are continuous with the lumen. At the middle portion (Fig. 8B), the space between

the central and two other lumens are occupied by tubular glands. The tubular glands penetrate the lamina propria mucosae and some of them are opened into the central lumen (Fig. 8G). Spermatozoa are found in the outer tubular glands

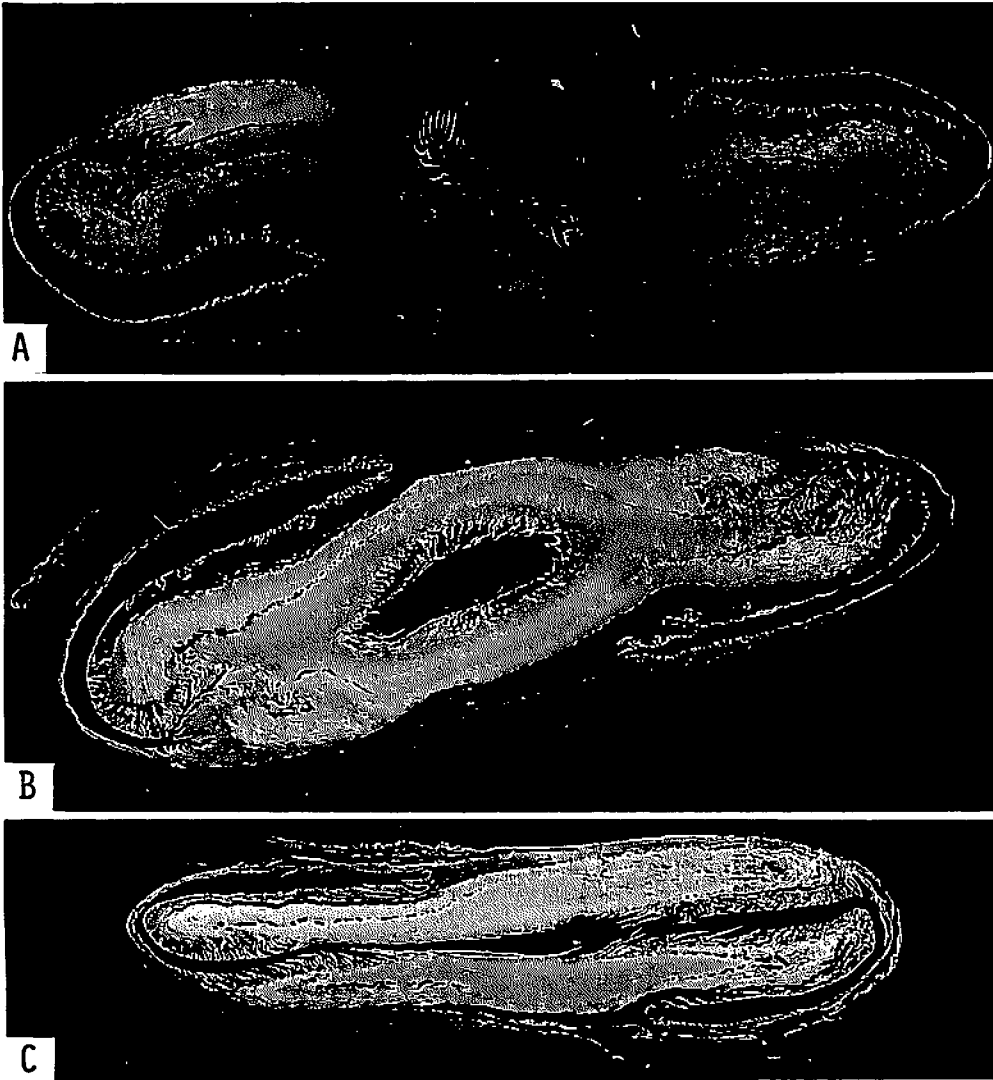


Fig. 8-1. Nidamental gland in *Mustelus manazo* and *M. griseus*.

- A. Transverse section of the upper portion. *M. manazo*.
- B. Transverse section of the middle portion. *M. manazo*.
- C. Transverse section of the lower portion. *M. griseus*.

(Fig. 8H). At the lower portion (Fig. 8C), the central lumen is continuous with the right and left lumens, and a large lumen is formed. The histology at this portion is the same as that at the upper and the middle. At the posterior end of the nidamental gland, only a small lumen exists and it is continuous with the lower portion of the oviduct.

Consideration

METTEN²⁷⁾, working with *Scylliorhynchus canicula*, indicated that the nidamental gland consisted of three zones, the albumen-secreting zone, mucus-secreting zone and shell-secreting zone. He also indicated that the shell-secreting tubule functions as a receptaculum seminis where many spermatozoa are found. In addition, he stated that the nidamental glands of all adult female *S. canicula* contain spermatozoa. This may be expected because *S. canicula* has no definite reproductive season. Spermatozoa were, however, found in the tubular glands of a female *Mustelus manazo* collected on March 3, 1973. *M. manazo* has a definite reproductive season, June to August, as described previously. It would be unexpected for the spermatozoa to be found in the non-reproductive period (having remained for about eight months after mating season). It may therefore be assumed that spermatozoa reaching the tubular glands in the reproductive season are left for a long time, and that the nidamental gland serves as a receptacle as was indicated by METTEN²⁷⁾, TEWINKEL²⁸⁾, working with *M. canis*, also found a large number of spermatozoa in the nidamental glands even after ovulation had ceased. As indicated by HISAW and ABRAMOWITZ^{25,26)} and TEWINKEL²⁹⁾, *M. canis* also has a definite mating season as found in the present *M. manazo* and *M. griseus*. According to MATTHEWS⁷⁾ and CHEN and

MIZUE²¹⁾, however, no traces of any such storage of spermatozoa were found in *Cetorhinus maximus* and *Galeorhinus japonicus* respectively.

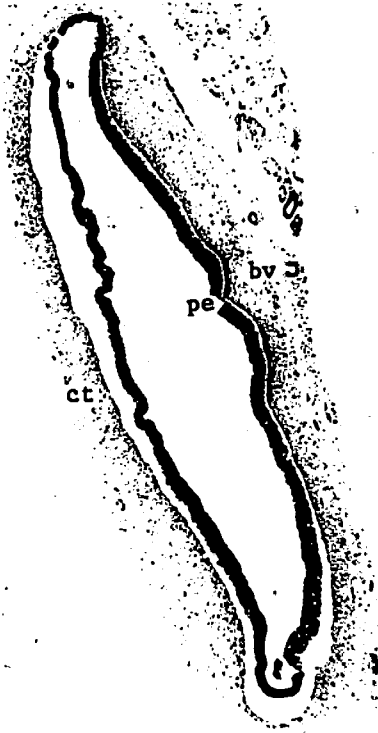
2.4. The uterus

The uterus is formed by modification of the oviduct. When the female shark is immature, the oviduct is very slender in shape. As the female reaches maturity, the oviduct extending posteriorly from the nidamental gland is gradually expanded, and the wall of the oviduct becomes much thicker than that of the oviduct which extends anteriorly. Preparation is thus made to receive fertilized eggs and to support embryos. The oviduct located posteriorly from the nidamental gland functions as the uterus after maturity of the female.

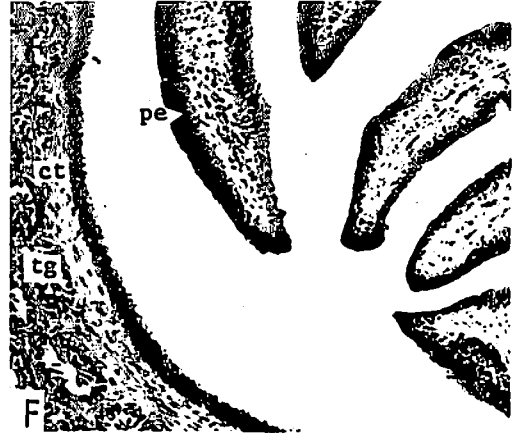
In both *Mustelus manazo* and *M. griseus*, the uterine wall is composed of the epithelium lining the internal surface of the uterus, the capillary network beneath the epithelium, connective tissue comprising the circular, longitudinal muscle layers and blood vessels, and the mesothelium covering the external surface of the uterus (Fig. 9A).

Although the uterine wall becomes thinner with the growth of embryos, no remarkable change occurs in the structure of uterus except in the epithelium composing the internal surface.

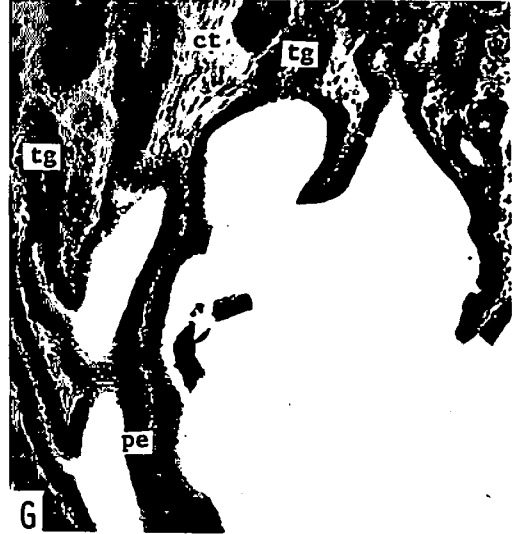
In *Mustelus manazo*, when the uterus contains fertilized eggs, the internal surface of the uterus is lined by two to three layers of cuboidal cells (Fig. 9B). When the embryos grow to more than 100 mm in total length, the internal uterine wall is covered with a simple epithelium of squamous cells. The epithelium is very thin and the cells are reduced in number (Fig. 9C). In the uterus containing the full grown embryos, the epithelium becomes



D




F



G



E



H

much thinner compared to that of embryos of about 120mm (Fig. 9D). In *M. griseus*, when the uterus contains the fertilized eggs, the internal epithelium of the uterus consists of a stratified cuboidal epithelium (Fig. 9E). The epithelium, however, consists of a single layer of cuboidal cells when the embryos are about 30mm in total length (Fig. 9F). In an uterus which has embryos of more than 100mm in total length, the internal surface is covered with a simple epithelium of tall columnar cells (Fig. 9G, H.I). The internal surface of an uterus containing the full grown embryos is again formed by a stratified cuboidal epithelium as found in early gestation (Fig. 9J).

The capillaries beneath the epithelium develop with embryonic growth. External to this capillary network is the connective tissue comprised of two distinct layers of smooth muscle cells; thick inner layer of circular muscle fibers and a thin outer layer of longitudinal fibers. The mesothelium consists of a single layer of cuboidal or squamous cells.

Consideration

In earliest gestation, the internal surface of the uterine wall, in both *Mustelus manazo* and *M. griseus*, is lined by stratified cuboidal cells. When the embryos grow to more than 100mm in total length, differences in the uterine

epithelium between *M. manazo* and *M. griseus* occur. In *M. manazo*, the epithelium becomes much thinner and the epithelial cells are reduced in number as compared to that in *M. griseus*.

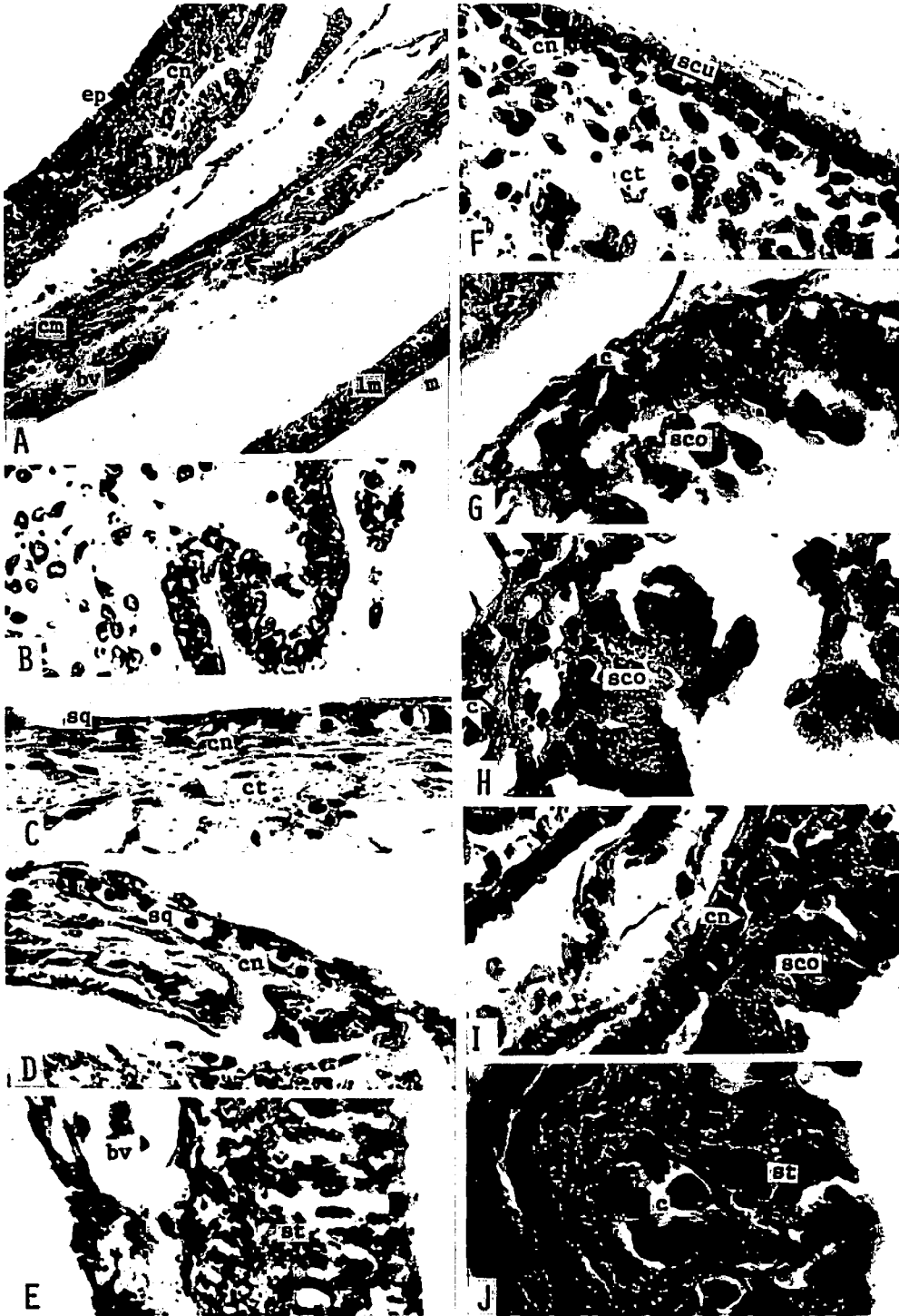
In *Mustelus griseus*, the internal surface of the uterus containing full grown embryos is covered with a stratified cuboidal epithelium as observed in early gestation. This change may relate to preparations for the future ovulation, fertilization and pregnancy. In *M. manazo*, this difference is not found in an uterus having the full grown embryos. The uterine epithelium in the late stage of gestation is much thinner than that in the middle stage of gestation. In *M. manazo*, regeneration of the epithelium appears to take place after parturition.

According to MAHADEVAN¹⁾, the internal uterine epithelium in *Scoliodon sorrakowah* changes from a simple cuboidal epithelium to a simple squamous epithelium as the pregnancy advances, and the epithelium is peeled off in certain places. In *S. palasorrah*, the internal uterine epithelium consisting of two to three layers of columnar cells at early gestation is reduced to a single layer of columnar cells in late gestation.¹⁾ WIDAKOWICH³⁰⁾, working with *Squalus acanthias*, described the internal epithelium of an uterus containing 10mm embryos as consisting of three to four layers of cells. He also mentioned that the composition

Fig. 8—II. Nidamental gland in *Mustelus manazo* and *M. griseus*.

- D. The nidamental gland of an immature female. *M. griseus*, × 20.
- E. A partial magnification of D. The internal surface is lined by the pseudostratified columnar epithelium. *M. griseus*, × 200.
- F. A partial magnification of the central lumen of A. The folds of the mucous membrane are lined by the ciliated pseudostratified epithelium of columnar cells. *M. manazo*, × 50.
- G. A partial magnification of the central lumen of B. Tubular glands penetrate the lamina propria mucosae, and some of them are opened into the lumen. *M. manazo*, × 50.
- H. A partial magnification of B. Spermatozoa are found in the outer tubular glands. *M. manazo*, × 50.

bv: blood vessel, ct: connective tissue, pe: pseudostratified epithelium, tg: tubular gland, sp: spermatozoa.



of the internal epithelium of the uterus may differ in component cell types according to the stage of gestation and the expansion of uterus.

2.5. The uterine compartment

In both *Mustelus manazo* and *M. griseus*, the uterine compartments are formed, according to the number of embryos, as the embryos grow (Fig. 14B, Fig. 11A, B). An embryo enclosed in an embryonic membrane is contained in each of the uterine compartment, and the embryonic membrane attaches to the internal surface of the compartment. The uterine compartments are formed by elevations or ridges of the internal surface of the uterine wall, that is, the elevations or ridges of the internal surface of the uterine wall wrap the embryos and yolk sacs from both sides and overlap to form the compartments. The ridges at the overlapping portion are not fused. The

ridges which later form the compartments can be observed as soon as the fertilized eggs are present in the uterus. The eggs are separated by these ridges. This situation occurs in both species (Fig. 10A). As the embryos grow, the ridges increase in height and then enfold the embryos forming chambers consistent with the number of embryos (Fig. 10B).

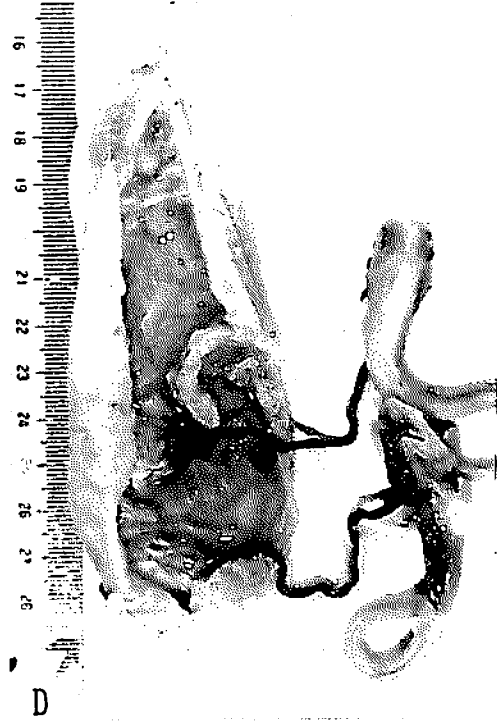
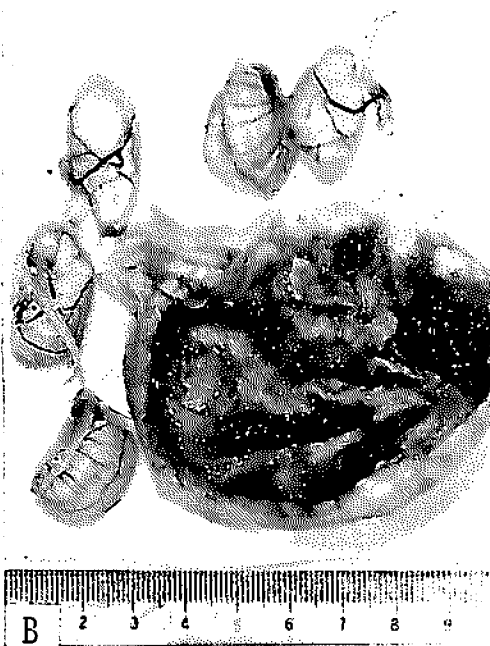
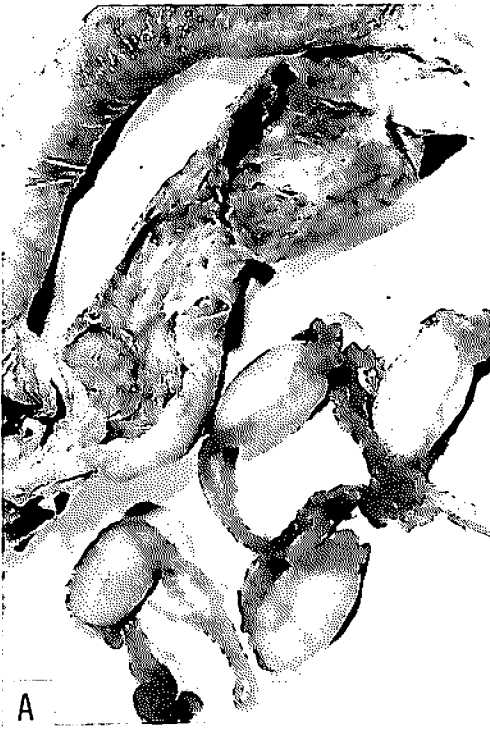In both species, the chambers are completely formed when the embryos are approximately 100mm in total length (Fig. 10D). At this stage, the chambers are positioned obliquely. As gestation advances, the chambers shift longitudinally. As the embryos reach the full term, the overlapping portion of the compartments becomes narrower and separated, and parturition then occurs (Fig. 11C).

The position of compartments found in uteri containing from two to five embryos is schematically shown in Fig. 12. This figure indicates that all the compartments are not formed in the same position, but

Fig. 9. The epithelial change in the uterus with the embryonic development in *Mustelus manazo* and *M. griseus*.

- A. The uterus consists of the internal epithelium, capillary network, connective tissue and mesothelium. *M. manazo*, × 50.
- B. The internal epithelium consists of two to three layers of cuboidal cells. This uterus contained the fertilized eggs. *M. manazo*, × 200.
- C. The internal surface is lined by the simple squamous epithelium. This uterus contained the 125mm-embryo. *M. manazo*, × 200.
- D. The internal epithelium becomes much thinner. This uterus contained the 270mm-embryo. *M. manazo*, × 200.
- E. The epithelium consists of the stratified epithelium. This uterus contained the fertilized eggs. *M. griseus*, × 200.
- F. The epithelium is formed by a single layer of cuboidal cells. This uterus contained the 33mm-embryo. *M. griseus*, × 200.
- G. The internal surface is lined by the single layer of tall columnar cells. This uterus contained the 104mm-embryo. *M. griseus*, × 200.
- H. The internal surface is covered with the simple columnar epithelium. This uterus contained the 124mm-embryo. *M. griseus*, × 200.
- I. The simple epithelium lines the internal surface of the uterus which contained the 235mm-embryo. *M. griseus*, × 200.
- J. The internal epithelium consists of the stratified cuboidal epithelium. This uterus contained the 278mm-embryo. *M. griseus*, × 200.

bv: blood vessel. c: capillary, cn: capillary network ct: connective tissue, cm: circular muscle fibers, ep: epithelium, lm: longitudinal muscle fibers, m: mesothelium, sco: simple columnar epithelium, scu: simple cuboidal epithelium sq: simple squamous epithelium, st: stratified epithelium.



are a little different in height ; in transverse section, the compartment 2 is positioned a little higher than the compartment 1, and the compartment 3 is higher than the compartment 2. The embryo developing in the lower positioned compartment is usually a little longer in total length than that of the higher.

Consideration

The wall of the compartment in *Mustelus manazo* is thinner than that in *M. griseus*.

In both *Mustelus manazo* and *M. griseus*, after parturition the wall of the uterine compartment appears to diminish in size as an uterus contracts, and preparation is made to receive fertilized eggs.

It has been reported that the uterine compartments are formed in many species such as *Mustelus antarcticus*³¹⁾, *M. laevis*^{32,33)}, *M. canis*²⁹⁾, *Carcharias lamia*³⁴⁾, *Carcharhinus falciformis*³⁵⁾, *Sphyrna tiburo*³⁶⁾ and *Galeorhinus japonicus*²¹⁾. Most viviparous species develop the uterine compartments though a few species such as *Heptranchias perlo* do not.³⁷⁾

The orientation of the compartments in *Mustelus antarcticus*³¹⁾ and *M. laevis*^{32,33)} is similar to that in *M. manazo* and *M. griseus*.

The uterine compartments shift longitudinally in *Mustelus manazo* and *M. griseus*. This change in position of the compartment is described in *Sphyrna tiburo* by SCHLERNITZAUER and GILBERT³⁶⁾. This

change is considered to be due to the increase in body length of the embryo, and facilitates parturition. The embryo positioned lowest appears to be first born in *M. manazo* and *M. griseus*.

2.6. The embryo

2.6.1. Embryonic growth and yolk absorption

In both *Mustelus manazo* and *M. griseus*, the fertilized eggs or embryos in the early development were found in the uteri of females collected during July and August. After this, the embryos grow rapidly and reach a total length of about 300mm by the next April. No embryos were found in the uteri of females during the period from late April through the early June. The fertilized eggs or the small-sized embryos were again found in the uteri of females during July and August (Fig. 4).

The absorption of yolk and the formation of the internal yolk sac during the course of embryonic development in *Mustelus manazo* are shown in Fig. 13 and Fig. 14A. The external yolk sac is connected with the anterior portion of the intestine by the ductus vitellointestinalis within the yolk stalk (Fig. 13A to F). The yolk in the external yolk sac is transported to the intestine through the ductus vitellointestinalis. When the embryos are about 50–60mm in total length, no yolk is observed in the intestine of the embryo by gross anatomy. Embryos at this stage

Fig. 10. Growth of embryos in *Mustelus griseus*.

- A. Fertilized eggs and uterus. Uterine ridges, which will form the uterine compartments, are observed. Each of the eggs is enclosed in an embryonic membrane.
- B. An uterus with five embryos of about 30mm in total length. Uterine ridges increase in height.
- C. The valvular intestine of the embryo of about 30mm in length. The internal surface is lined by a simple epithelium of tall columnar cells. × 50.
- D. An uterus with three embryos of 93, 103 and 104mm in total length. The basal surface of the yolk sac is attached to the uterine wall. Two embryos are taken out of the uterus. Another is remained in the uterine compartment.

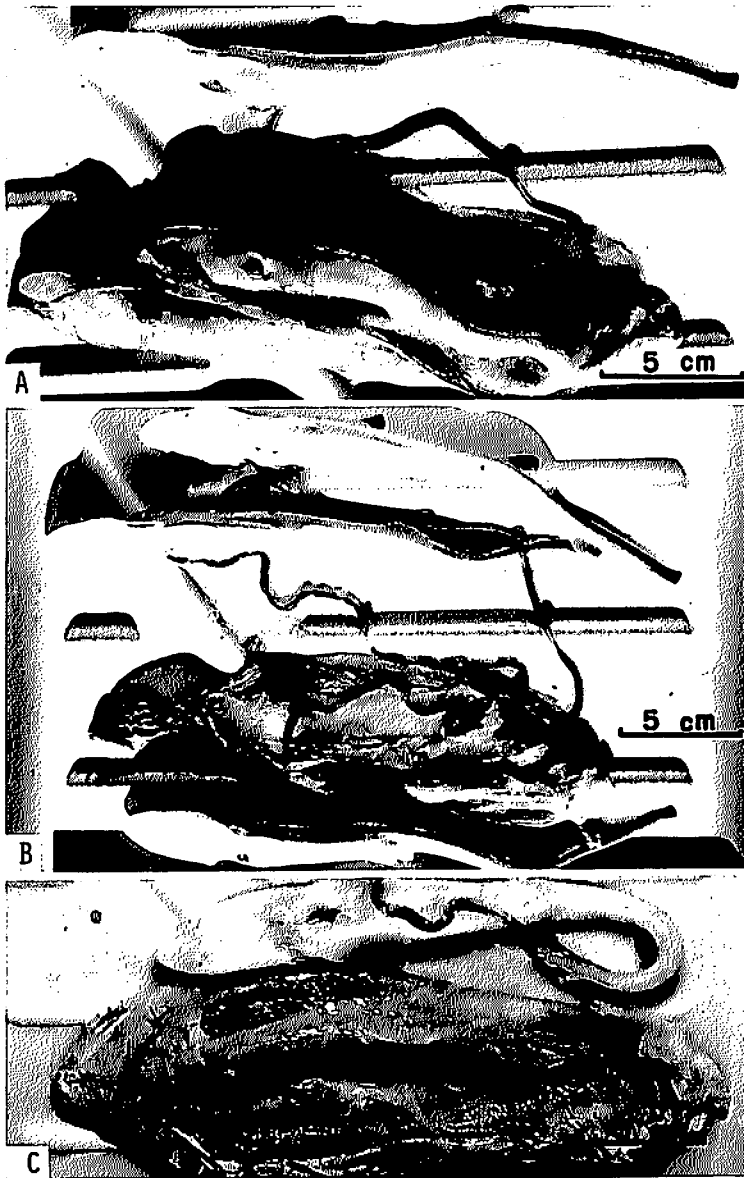


Fig. 11. Growth of embryos in *Mustelus griseus*.

- A. An uterus with three embryos of 235, 236 and 237 mm in total length. The dorsal side of the uterus is dissected. Two embryos are present in the uterine compartments.
- B. The placenta is established in the posterior end of the uterine compartment on the ventral wall of uterus. (same specimen as A).
- C. An uterus with four embryos of 272, 280, 292 and 294 mm in total length. The overlapping portion of the uterine compartment is separated.

have external gill filaments of 6–7mm long protruding from the gill openings. In embryos growing to more than 100mm in total length the intestines are filled with yolk mass. As the same time, external gill filaments disappear. In an embryo of 142mm in total length, the ductus vitellointestinalis is a slightly expanded at the connecting portion with the intestine (Fig. 13C), i.e., the formation of the internal yolk sac has begun. When the embryos are about 170–180mm in length, the internal yolk sac develops up to about 1–1.5mm in diameter and 4–5mm in length (Fig. 13D). The internal yolk sac reaches a maximum in diameter

(4–5mm) and length (13–15mm) when the embryos are about 210–220mm in total length (Fig. 13E). At this stage, almost all the yolk in the external yolk sac is consumed and the yolk sac diminishes in size. The yolk in the external yolk sac is completely absorbed when the embryos grow to more than 230mm in length, and the external yolk sac becomes small and globular (about 1mm in diameter) in shape (Fig. 13F). At the same time, the internal yolk sac becomes small (about 1–2mm in length) in size and soon disappears (Fig. 13F). The intestine of the embryo, however, growing to more than 250mm in total length is still filled with the yolk

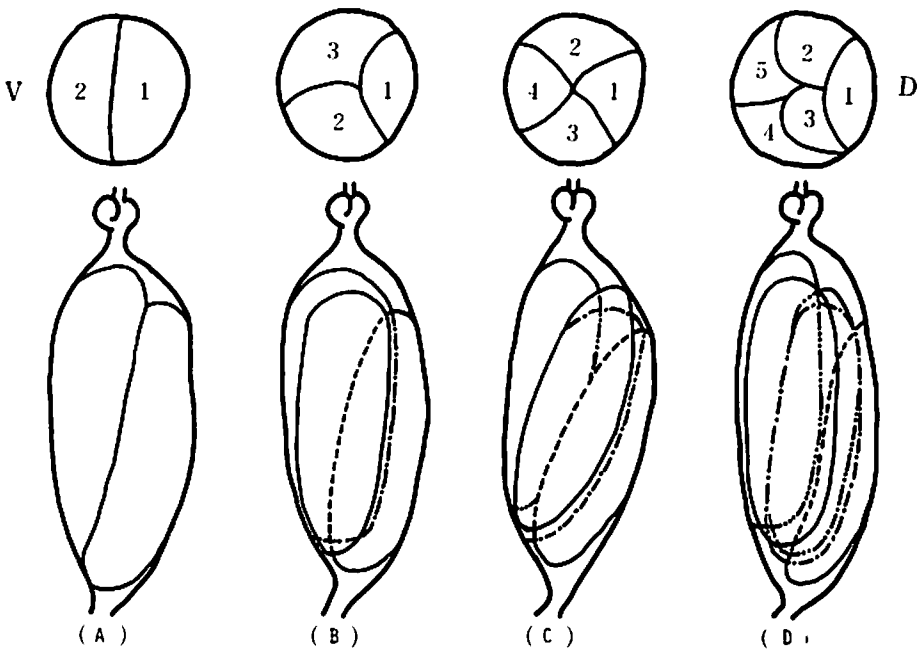


Fig. 12. Position of the uterine compartments in *Mustelus griseus*.

A. adult: 945mm, embryos: 140 and 151 mm in total length.

B. adult: 868mm, embryos: 235, 236 and 237 mm in TL.

C. adult: 901 mm, embryos: 112, 118, 119 and 124 mm in TL.

D. adult: 951 mm, embryos: 141, 143, 147, 150 and 152 mm in TL.

Upper: transverse section of the uterus, lower: longitudinal section.
D: dorsal side of the uterus, V: ventral side.

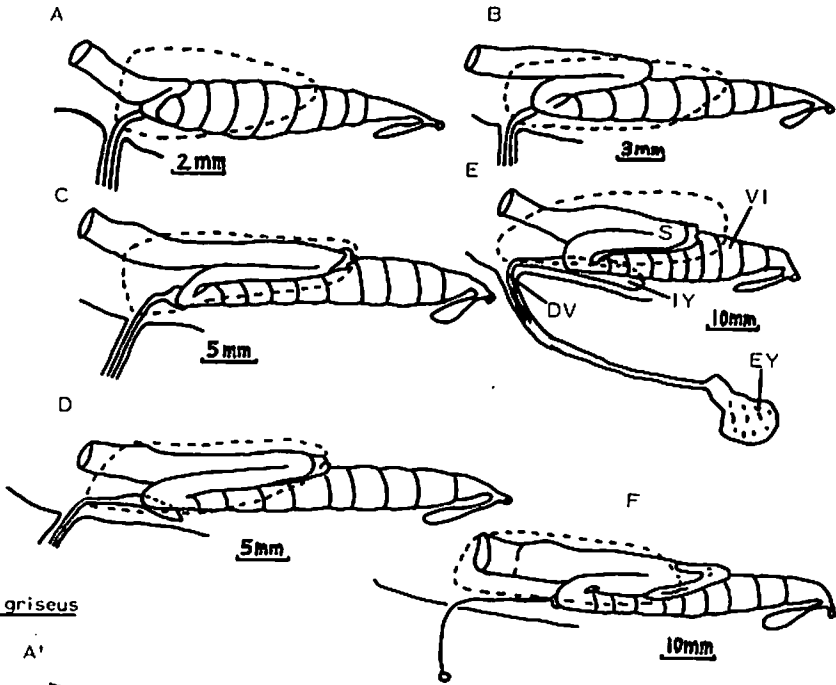
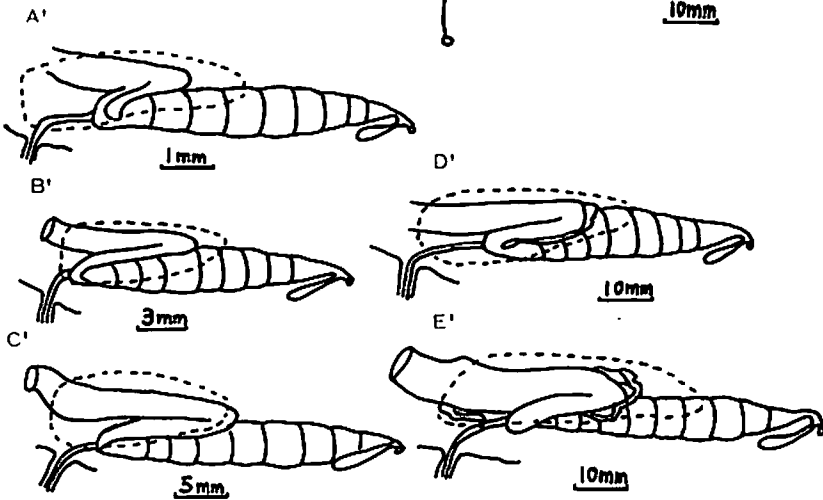
Mustelus manazoMustelus griseus

Fig. 13. Diagrammatic lateral aspects of viscera of embryos in *Mustelus manazo* (A to F) and in *M. griseus* (A' to E'). A: 48mm, B: 84mm, C: 142mm, D: 172mm, E: 216mm, F: 250mm, A': 36mm, B': 90mm, C': 138mm, D': 230mm, E': 273mm in total length. DV: ductus vitellointestinalis, EY: external yolk sac, IY: internal yolk sac, S: stomach, VI: valvular intestine. Broken line: left lobe of liver.

mass.

In *Mustelus manazo*, the yolk stalk increases in length as the embryo grows, reaching its maximum length when the embryo is about 150mm in total length. The yolk stalk, however, then decreases in length as the yolk in the external yolk sac is consumed. Thus, the very short, slender stalk and contracted external yolk sac are incorporated into the body of the embryo when the yolk in the external yolk sac is completely absorbed (Fig. 14A).

In *Mustelus griseus*, as found in *M. manazo*, the ductus vitellointestinalis connects the yolk sac with the anterior portion of the intestine (Fig. 13A' to E'). A small quantity of yolk is already found in the valvular intestine of an embryo of about 30mm in total length (Fig. 10C). At this stage, the internal surface of the intestine is lined by a single epithelium of tall columnar cells. External gill filaments are seen to protrude from the gill openings when the embryo is about 30–50mm in total length. The formation of placenta commences when the embryo is about 90–100mm in length. At this stage, yolk sac still contains a large quantity of yolk. The placenta is located in the posterior end of each uterine compartment along the ventral wall of the uterus (Fig. 11A, B). The placenta is fully established when the embryo is about 150mm in total length. No yolk is found in the yolk sac of the embryo which grows to more than 150mm in total length. The yolk, which has been contained within the yolk sac, is transported to the intestine where it is stored as the embryo grows. A relatively large quantity of yolk is still present in the intestine even after the placenta is established. The quantity of yolk stored in the intestine of the embryo reaches a maximum in volume (suggested by the size of the intestine) when the embryo is about 230–240mm in total length (Fig. 13D). After this stage

the yolk contained in the intestine becomes consumed as the embryo reaches full term. The internal yolk sac as found in *M. manazo* is not formed throughout the whole stage of embryonic development (Fig. 13A' to E').

In *Mustelus griseus*, the umbilical stalk continues to increase in length with embryonic growth, and attains a maximum of 230mm in length when the embryo is about 280mm in total length.

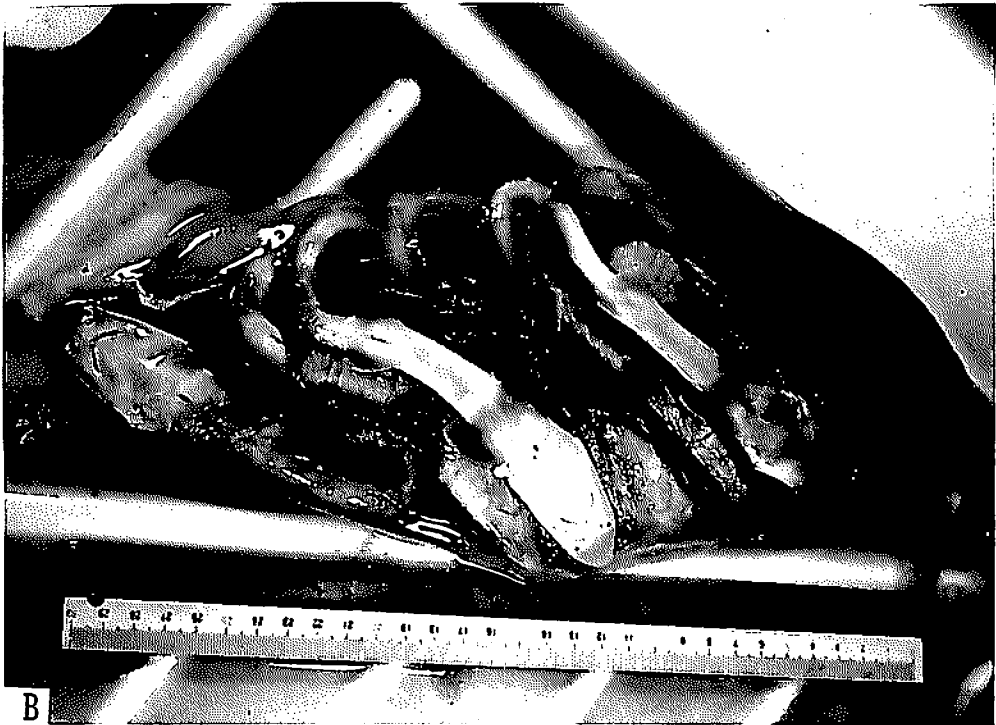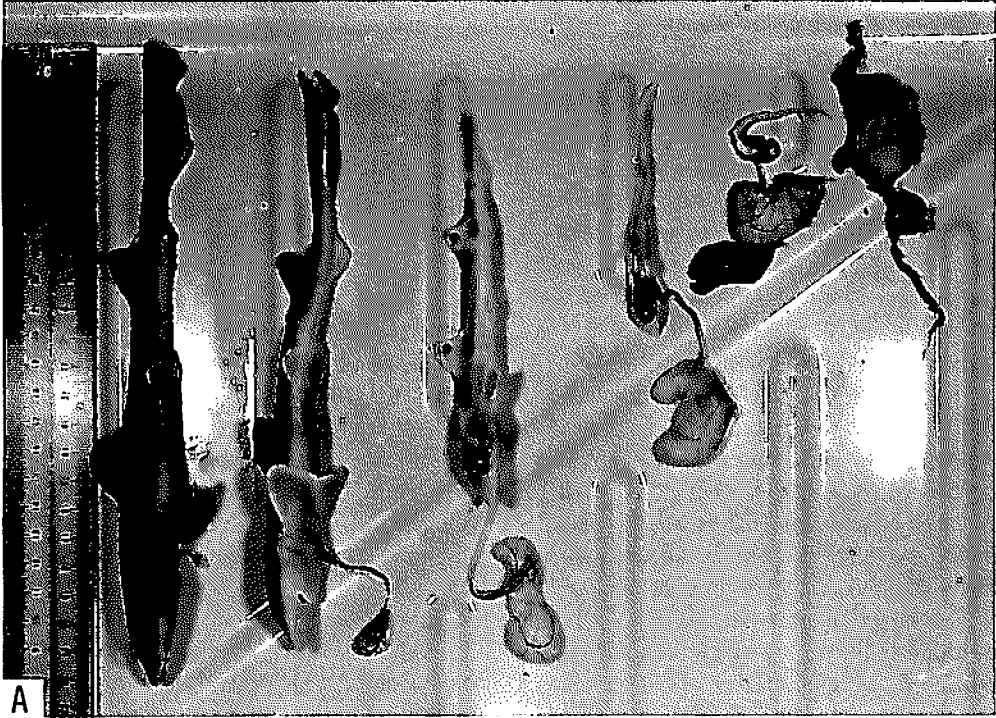
In *Mustelus manazo* and *M. griseus*, when the embryos attain a total length of 270–290mm, the overlapping portion of the uterine compartment is separated, and the embryo enclosed in the embryonic membrane is exposed (Fig. 11C). In *M. griseus*, the foetal placental portion at this stage is easily separated from the maternal portion.

In both species, the embryos are usually positioned with their heads pointing anteriorly in the uterine compartments.

2.6.2. Relationship between adult length and the number of embryos per litter

The relationship between the adult length and the number of embryos per litter is shown in Fig. 15. In *Mustelus manazo*, when the adults are 630–851mm in total length, the number of embryos per litter ranges between one and eight. In *M. griseus*, when the adults are 835–1023mm, it ranges between five and 16. In both species, the number of embryos per litter increases with adult length.

In the uterus where parturition seems to occur imminently, the embryo growing in the lower positioned uterine compartment is about 2–3mm longer in total length than that in the higher in both species. A difference in total length between the smallest and the largest embryos near full term in the same adult ranges from 2 to 20mm in *Mustelus*



manazo when the number of embryos per litter is between three and eight. In *M. griseus*, the total length difference varies from 12 to 30mm when the number of embryos per litter is between six and ten. With a few exception, however, the average length of the embryos per litter is almost the same among the specimens examined, i.e., the embryos near full term average about 290mm in total length in both species.

Among the specimens of *Mustelus manazo*, the smallest gravid female was 630mm in total length. In *M. griseus*, the smallest was 760mm and this specimen had the fertilized eggs in uteri.

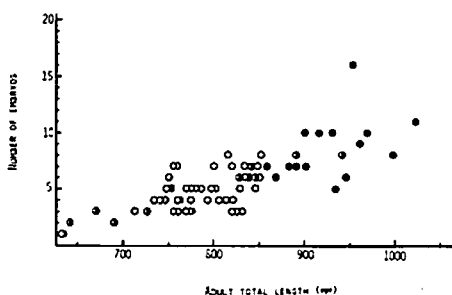


Fig. 15. Relationship between adult length and the number of embryos per litter in *Mustelus manazo* (open circle) and *M. griseus* (closed circle). The semi closed circle: *M. manazo* from the northern waters of the East China Sea.

2.6.3. Consideration

In both *Mustelus manazo* and *M. griseus*, the fertilized eggs and embryos in early

development are found during July and August. Thus, the gestation appears to commence during July and August. When the embryos attain the total length of 270–290mm in March and early April, the uterine compartments are opened. In *M. griseus*, the union between the foetal and maternal tissues at this stage is less tight compared to that at about 230mm in length. Moreover, no embryos are found in the uteri of females in late April and May. However, many young about 300mm in total length with a new umbilical scar are found at the same time. These facts suggest that parturition should occur during April and May when the embryos are approximately 300mm in total length. Gestation period in both species is therefore estimated to be about ten months.

HISAW and ABRAMOWITZ^{25,26}, working with *Mustelus canis* in the waters off Massachusetts, reported that parturition occurs during late May and early June with about 16 embryos, about 35cm in length, being born per litter, and that gestation period is ten months. TWINKEL²⁹, also working with *M. canis* in the same waters, is of the opinion that this species has a gestation period of about ten months duration, and that embryos, about one foot (30cm) in length, are born in May and possibly during late April and early June.

In *Mustelus griseus*, the well developed placenta is established when the embryos are about 150mm in total length, and this stage occurs about three and a half to four months into the gestation period. In *M. canis*, the placenta is firmly attached to the uterine wall when the embryos are

Fig. 14. Growth of embryos and the uterine compartments in *Mustelus manazo*.

- A. Absorption of yolk with advancing embryonic development. From right, 22 (attached to the yolk sac), 52, 90, 145, 206 and 230mm in total length.
- B. An uterus with eight embryos between 230 and 247mm in total length. Yolk in the external yolk sac is completely absorbed at this stage. Each of the embryos is contained in the uterine compartment.

about 150mm in length^{25,26}).

It has been reported that an internal yolk sac is formed in the species such as *Squalus acanthias*³⁸, *Etmopterus lucifer*³⁹ and *Galeorhinus japonicus*²¹. Concerning *Mustelus* species, an internal yolk sac is formed in the embryo of *M. manazo*, but it is not formed in *M. griseus* throughout embryonic development. It may be said that the internal yolk sac is formed in species which do not develop the placenta. The internal yolk sac in *M. manazo* is very small in size compared with those in *S. acanthias* and *E. lucifer*, correspondingly, it is only 4–5mm in diameter and 13–14mm in length when it reaches its maximum size. In both *S. acanthias* and *E. lucifer* the internal yolk sac still contains a relatively large amount of yolk even after the external yolk sac remnant is incorporated into the body of the embryo. In *M. manazo*, however, the internal yolk sac diminishes in size already when the external yolk sac remnant is being incorporated into the body of the embryo. It may be thus considered that in *M. manazo* the internal yolk sac does not have an important role in storing and transporting yolk mass to the intestine.

In *Mustelus manazo*, since no placenta develops, the embryo is mainly nourished by yolk. The yolk stored in the intestine appears to be present for a while after parturition, because the intestine of a near full termed embryo contains a relatively large quantity of yolk. Iwai³⁹, working with *Etmopterus lucifer*, described that a considerable amount of yolk mass is contained within the duodenum and spiral valve of the embryo in the late stage of gestation period. In *M. griseus*, although the yolk stored in the intestine remains after the establishment of placenta, it seems to be completely consumed before parturition. Two stages are thus considered in respect to the embryonic development ;

1) the stage when the embryo is mainly nourished by yolk, before the establishment of placenta, 2) the embryo is nourished by both yolk and placenta. In the second developmental stage, as the quantity of yolk is reduced with growth of embryo, nutritional supply for the embryo appears to become dependent upon the placenta.

In both *Mustelus manazo* and *M. griseus*, the number of embryos per litter increases with adult length. This relationship is also reported in *M. manazo* in the northern waters of the East China Sea²⁴ and *Galeorhinus japonicus*²¹. No great variation in number of embryos is found between *M. manazo* by TESHIMA et al.²⁴ and the present *M. manazo*. According to Iwai³⁹, the number of embryos per litter in *Etmopterus lucifer* does not vary according to the adult length, that being usually eight. In *Carcharhinus dussumieri*, occurring in the South China Sea, the number of embryos is usually two per litter²⁰.

In both *Mustelus manazo* and *M. griseus*, since embryos at different lengths are growing simultaneously in the same adult, a litter of embryos are expected to be different in length when they are born. The length difference between the smallest and the largest embryos near full term in the same adult increases with the number of embryos per litter. It may be, however, said that the length of the embryos at birth do not tend to decrease even though the number of embryos per litter increases.

2.7. The placenta

Of the Japanese *Mustelus* species, only *M. griseus* establishes the placenta during gestation. The placenta is not formed in *M. manazo* throughout gestation.

2.7.1. Establishment of the placenta

The small grooves in the surface of the yolk sac interdigitates with small folds in

the internal uterine wall to establish the placenta (Fig. 16). The placenta thus consists of two portions: maternal placenta (internal uterine wall) and foetal placenta (yolk sac wall). The interdigitation occurs when the embryos are 90–100mm in total length. Sequential histological sections at the foetal-maternal junction of the placenta during the stages from the commencement of placentation to near parturition are presented in Fig. 17A, B, I, K. These figures indicate the successive stages in the development of the placenta.



Fig. 16. Simplified drawing of the placenta in *Mustelus griseus*. The placenta consists of a maternal (solid black) and a foetal (dotted area) portion. Hatching: blood vessels.

When the embryos are approximately 100mm in total length, the union between foetal and maternal tissues is not yet established (Fig. 17A). When the embryos are about 120mm in total length, the


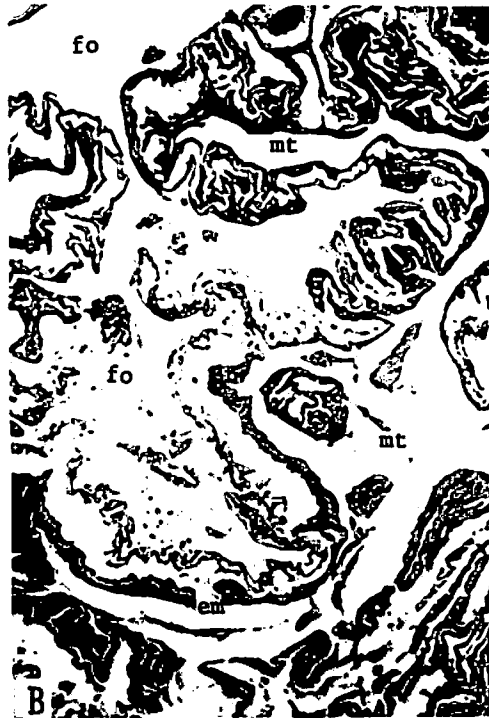

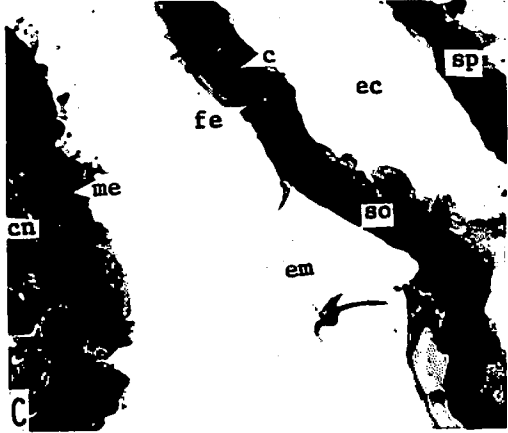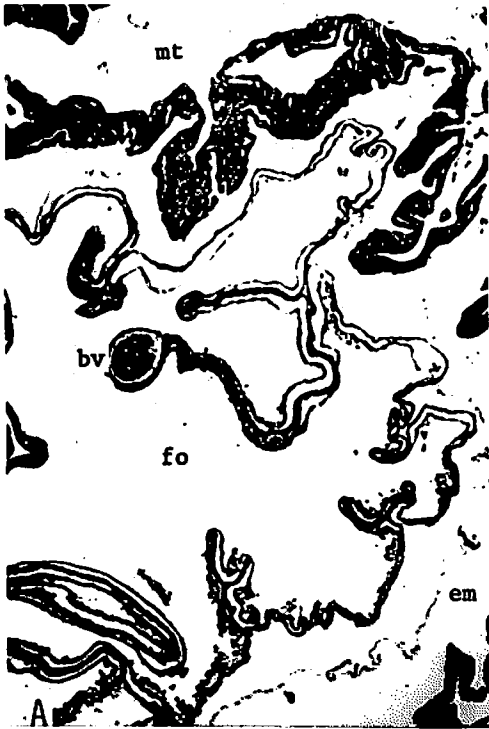
grooves in both tissues become more intricate than in the previous stage (Fig. 17B). When the embryos grow to about 230mm in length, the grooves in both tissues are highly interdigitated (Fig. 17I). At about 280mm in total length (near full term) there are no further interdigitation (Fig. 17K), rather, the union appears to be less tight compared with that at about 230mm in total length.

The membrane intervening between the foetal and maternal portions of the placenta (Fig. 17A, B) is the embryonic membrane.

2.7.2. Histology of the placenta

As was mentioned in the previous section, the uterine wall consists of the epithelium, the capillary network, the connective tissue and mesothelium. The yolk sac wall is composed of two walls: the splanchnopleure (the internal wall) and the somatopleure (the external wall). In the present investigation, observations were concentrated on the changes in the internal epithelium of the uterus and the somatic ectoderm of the yolk sac, which form the foetal-maternal junction of the placenta.

The epithelium of the maternal placenta is very thin compared to the simple epithelium lining the other part of the same uterus. The capillaries beneath the maternal placental epithelium are more developed than in the other portions of the uterus. When the embryos are about 100–120mm in total length, the squamous cells composing the maternal placental epithelium have diminished in number (compared Fig. 9G with Fig. 17C, Fig. 9H with Fig. 17D). When the embryos grow to more than 150mm in length, the greater portion of the epithelium of the maternal placenta disappears and the capillary network underlying the epithelium comes into direct contact with the embryonic membrane. The capillaries are well



developed (Fig. 17G, J.L). The internal uterine epithelium near the placental area (but not participating in the placenta) is also thin (Fig. 17E).

It is clearly observed that the foetal placental epithelium is greatly reduced in thickness compared to the other areas of the same yolk sac wall. When the embryos are about 100–120mm in total length, the epithelium of the foetal placenta is composed of squamous cells (Fig. 17C, D). When the embryos are more than 150mm in total length, the foetal epithelium almost degenerates as observed in the maternal tissue, and the foetal capillary network abuts against the embryonic membrane. The capillaries are well developed (Fig. 17G, J.L). Thus, at the foetal-maternal junction of a placenta nourishing an embryo more than 150mm in total length, the foetal capillaries and maternal capillaries are bounded by the embryonic membrane. The foetal capillaries are more developed than the maternal ones (Fig. 17G, J. L).

In the yolk sac wall which is not participating in the placenta, there is an extra-embryonic coelom between the splanchnopleure and the somatopleure (Fig. 17H). In a foetal placenta of an embryo more than 150mm in length, the extra-embryonic coelom is obliterated by the fusion of the splanchnic mesoderm and the somatic mesoderm, and the yolk sac wall becomes very thin (Fig. 17G, J.L).

At the beginning of the placentation, the extra-embryonic coelom still persists, but the ectoderm of the somatopleure is reduced in thickness (Fig. 17C, D).

In the connective tissue of the maternal placenta in the two uteri (which contain the embryos of 142mm and 278mm in total length respectively), spaces covered with the simple epithelium of tall columnar cells are observed (Fig. 17F, K). These appear to be mucus-secreting chambers.

2.7.3. Consideration

In a well developed placenta of the present *Mustelus griseus*, the epithelia of both maternal and foetal tissues almost degenerate and the capillary networks of both tissues come in contact with the embryonic membrane at the foetal-maternal junction. This permits the efficient exchange of substances between the mother and the embryos. The foetal capillaries are more developed than the maternal ones. The well developed capillaries of the foetal placenta enables a very efficient exchange of substances.


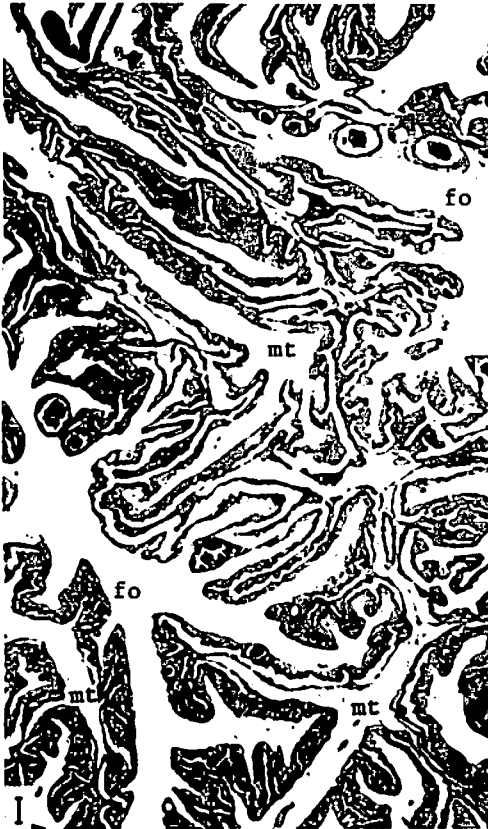
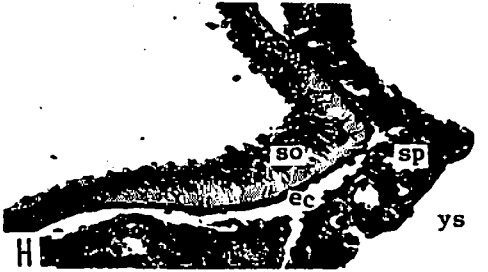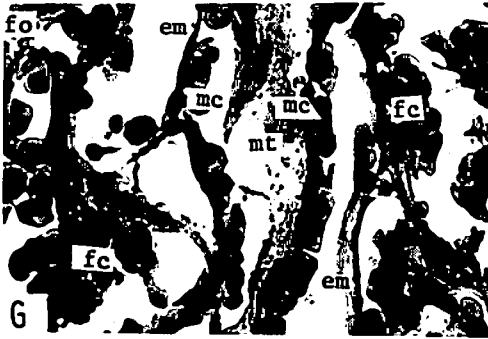

The embryonic membrane encloses an embryo until parturition. All exchanges between the mother and the embryos occur through this membrane. The embryonic membrane thus plays an important role in support, nutrition, respiration and excretion of the embryo.

The embryonic membrane in the mammalian, such as the amnion, the yolk

Fig. 17—I. The sequent development of the placenta in *Mustelus griseus*.

- A. Placenta nourishing the 104 mm-embryo, $\times 10$.
- B. Placenta nourishing the 124 mm-embryo, $\times 10$.
- C. Placenta. A partial magnification of A, $\times 268$.
- D. Placenta. A partial magnification of B, $\times 268$.
- E. The internal epithelium of the uterus near the placental area, developing the 142mm-embryo, $\times 67$.
- F. Placenta nourishing the 142 mm-embryo and the mucus-secreting chamber, $\times 67$.

bv: blood vessel, c: capillary, cn: capillary network, ct: connective tissue, ec: extra-embryonic coelom, em: embryonic membrane, fe: foetal epithelium, fo: foetal tissue, me: maternal epithelium, ms: mucus-secreting chamber, mt: maternal tissue, so: somatopleure, sp: splanchnopleure.



sac and the allantois, are differentiated from the endoderm, mesoderm and ectoderm during the early embryonic development^{40,41}). The embryonic membrane in *Mustelus griseus* is, however, already formed before the development of an embryo. Moreover, it is observed that the membrane is not formed by cells. TEN CATE-HOEDEMARKER³²), working with the placenta of *M. laevis*, also indicated that there is a membrane, which is not formed by cells, between the foetal and maternal placental tissues. The embryonic membrane in *M. griseus* is thus obviously different both embryologically and histologically from that in the mammalian.

Concerning the member of *Mustelus* species distributed in the world's ocean, BIGELOW and SCHROEDER⁴²) stated that certainly two, and probably three, recognizably distinct species occur in the eastern Atlantic, four in the western Atlantic, four along the western coasts of America; also at least two or three and perhaps more occur in the western Pacific, in the Australia-New Zealand region and in the Indian Ocean together with its tributary seas. Of these, it has been reported that four species establish the placenta and two do not. No clear relationship between uteri and embryos has not yet been determined in the remaining species. Placental species: *M. norrisi*⁴³), *M. mustelus*⁴²), *M. canis*^{25,26,42}) and *M. laevis*^{32,33,44}). Non-placental species:

*M. vulgaris*⁴⁴) and *M. antarcticus*⁴⁴).

Whether or not the placenta is developed seems to be one of the most important characteristics for identifying the species of the genus *Mustelus*. BLEGVAD⁴⁵), working with taxonomy on fishes of the Iranian Gulf, indicated that *M. manazo* develops the placenta. In the illustration, a long umbilical stalk connects the foetal placenta with an embryo. As has been described here no placenta is formed in *M. manazo*. *M. manazo* identified by BLEGVAD⁴⁵) is therefore obviously a different species from the *M. manazo* defined here by the present author.

Histological variations occur at the foetal-maternal junction of the placenta. In *Carcharhinus falciformis*, the maternal epithelium consisting of columnar cells and the greatly reduced foetal epithelium are in touch with the embryonic membrane³⁵). The greatly reduced epithelia of the foetal and maternal placenta are in contact with the embryonic membrane in *Sphyrna tiburo*³⁶). In *Mustelus laevis*, the greatly reduced epithelium of the maternal placenta and the foetal capillaries abut against the embryonic membrane³²). In *Scoliodon palasorrah*, the greatly reduced maternal epithelium is directly in touch with the greatly reduced foetal epithelium. Both epithelia consist of very few flat cells¹). In *S. sorrakowah*, the reduced foetal epithelium is directly in contact with

Fig. 17—II. The sequent development of the placenta in *Mustelus griseus*.

- G. Placenta. A partial magnification of F, × 268.
- H. Yolk sac wall not participating in the placenta, nourishing the 235 mm-embryo, × 67.
- I. Placenta nourishing the 235 mm-embryo, × 10.
- J. Placenta. A partial magnification of I, × 268.
- K. Placenta nourishing the 278 mm-embryo, × 10.
- L. Placenta. A partial magnification of K, × 268.

ec: extra-embryonic coelom, em: embryonic membrane, fc: foetal capillary, fo: foetal tissue, mc: maternal capillary, me: maternal epithelium, ms: mucus-secreting chamber, mt: maternal tissue, sn: splanchnic endoderm, sp: splanchnopleure, so: somatopleure, ys: yolk sac.

the maternal epithelium consisting of a single layer of columnar cells, at the basal, and of cuboidal cells, at the lateral portions^{1,2}). In *M. griseus* in the present investigation, both foetal and maternal capillaries are bounded by the embryonic membrane. Also, an illustration of the placenta in *Carcharias glaucus* indicates that the epithelium of the foetal placenta is greatly reduced⁴⁶). It appears to be common to the above species that the epithelium of the foetal placenta is greatly reduced in thickness. The placenta of *M. laevis* is relatively similar to that of *M. griseus*.

TEN CATE-HOEDEMARKER³²) uses the terminology of endothelio-endothelial for the placenta of *Mustelus laevis*. SCHLERNITZAUER and GILBERT³⁶) refer to the placenta of *Sphyrna tiburo* as an epithelio-shell membrane-epithelial placenta. The placenta of *M. griseus* in the present investigation may be expressed as the endothelio-embryonic membrane-endothelial.

Most placental species establish the placenta during the middle stage of gestation, e.g., placenta commences at about three and a half months after fertilization in *Sphyrna tiburo*³⁶), and at about three months after fertilization in *Mustelus griseus*²²). It has been, however, investigated that *Scoliodon sorrakowah* and *S. laticaudus* (MÜLLER et HENLE) establish the placenta

during the earliest stage of gestation, that is, *S. sorrakowah*²⁾ forms the placenta at the 3mm-stage of the embryonic development, and the placentation commences soon after implantation in *S. laticaudus*⁴⁷). These two species, *S. sorrakowah* and *S. laticaudus*, are distinguishable from the other species in having following characteristics; 1) The yolk is not contained in the yolk sac even in the earliest stage of gestation, 2) no embryonic membrane intervene between the foetal and maternal placental tissues, 3) the maternal placenta consists of the four components, (from the foetal to the maternal end), the trophonematous cup, the trophonematous cord, the trophonematous bulb and the trophonematous stalk²⁾.

2.8. The yolk stalk

2.8.1. Structure of the yolk stalk

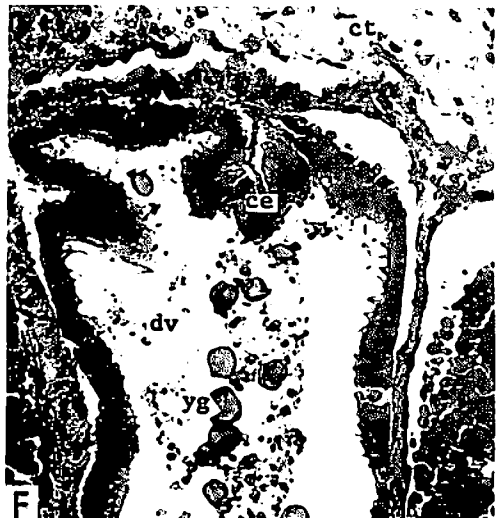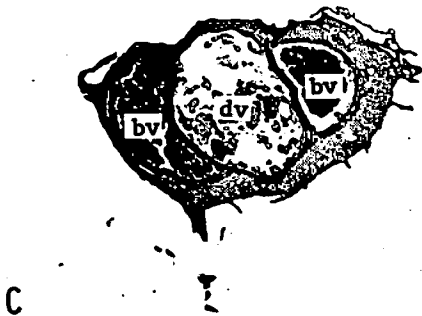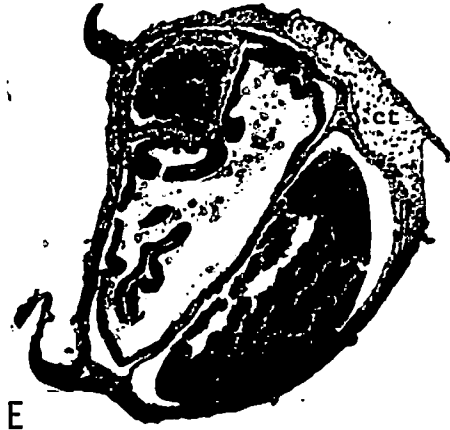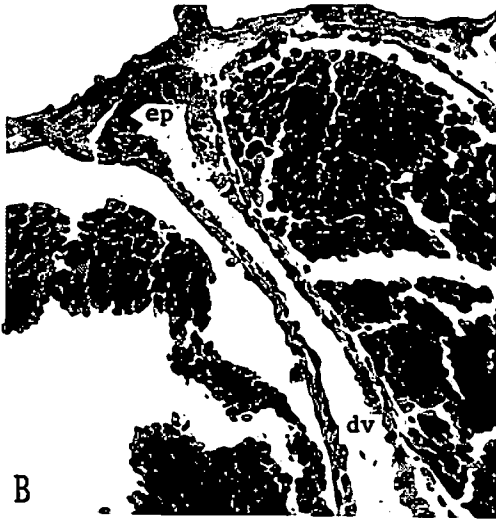
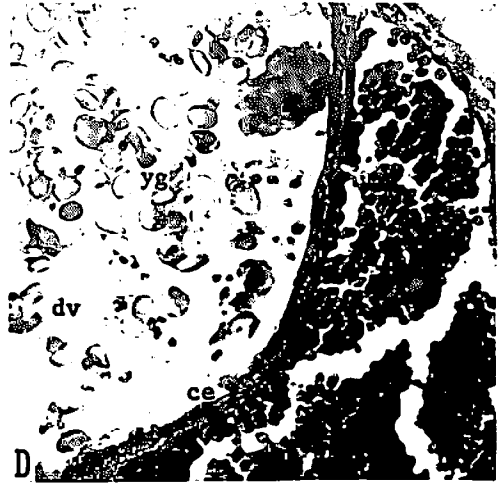
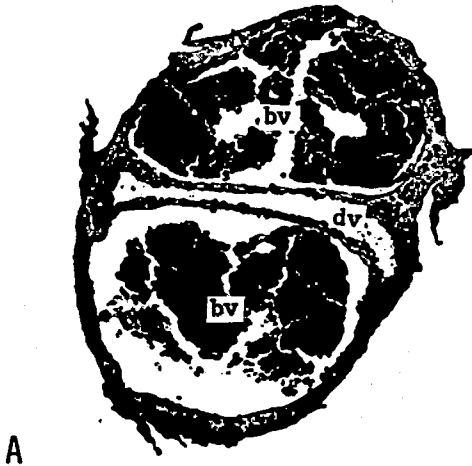
The yolk stalk connects the embryo with the external yolk sac. In *Mustelus griseus*, the yolk stalk is referred to as the umbilical stalk after the placenta is established. In both *M. manazo* and *M. griseus*, the yolk (umbilical) stalk contains three channels; vitelline (umbilical) artery, vitelline (umbilical) vein and ductus vitellointestinalis (Fig. 18).

Each of wall of the vitelline artery and vein consists of three layers; tunica intima,

Fig. 18—I. Yolk stalk in *Mustelus manazo* and *M. griseus*.

- A. Transverse section of yolk stalk, embryo: 52mm in total length. *M. manazo*, × 50.
- B. A partial magnification of A. The internal epithelium of the ductus vitellointestinalis is lined by a single layer of cuboidal cells (at the lateral portions) and squamous cells. × 200.
- C. Transverse section of yolk stalk, embryo: 90mm, *M. manazo*, × 20.
- D. A partial magnification of C. The ductus vitellointestinalis is lined by the simple ciliated cuboidal epithelium. × 200.
- E. Transverse section of yolk stalk, embryo: 230mm. *M. manazo* × 26.8.
- F. A partial magnification of E. The internal surface of the ductus vitellointestinalis is covered with the simple epithelium of tall columnar cells. Cilia are well developed. × 200.

bv: blood vessel, ce: ciliated epithelium, ct: connective tissue, dv: ductus vitellointestinalis, ep: epithelium, yg: yolk globules.



tunica media and tunica adventitia (Fig. 18N). The tunica intima is formed by the endothelium and the thin layer of the elastic fibers. The endothelium is lined by a single layer of elongated squamous cells. The tunica media is a layer of the smooth muscle, and this layer is thicker in the artery. The tunica adventitia consists of the fibrous connective tissue. In most sections of the stalks, the tunica adventitia does not exist due to the fusion between the extra-embryonic somatopleure and the splanchnopleure (Fig. 18A, C, E, L). The lumen of the vein is larger than that of the artery. In *Mustelus griseus*, the tunica media of both the vitelline artery and vein develop and become thicker as the embryo grows, especially after establishment of the placenta (Fig. 18L). On the other hand, in *M. manazo*, when the embryos are less than 100mm in total length, it is not easy to distinguish between the artery and the vein by the thickness of the tunica media or the size of the lumen (Fig. 18A, C). When the embryos grow to more than 200mm in length, both artery and vein become smaller in size with the contraction of the yolk stalk.

The ductus vitellointestinalis is lined by a simple epithelium, a portion or the whole of which has cilia (Fig. 18K). The epithelium changes according to the embryonic development and differs in both

species.

The stalk sheath is composed of a fibrous connective tissue where large blood vessels are developed. In some portions of stalk the extra-embryonic coelom exists between the sheath and the artery and the vein.

The external surface of the stalk is covered with a simple squamous epithelium in *Mustelus manazo* (Fig. 18A, C, E), though the epithelium changes with the embryonic development in *M. griseus*. When the embryo is about 30mm in total length, the external epithelium consists of a single layer of squamous cells. The epithelium changes to a simple cuboidal epithelium when the embryo is about 90mm in length. Furthermore, when the embryo grows to more than 100mm in total length, the epithelium is lined by a single layer of short columnar cells (Fig. 18G, I, L).

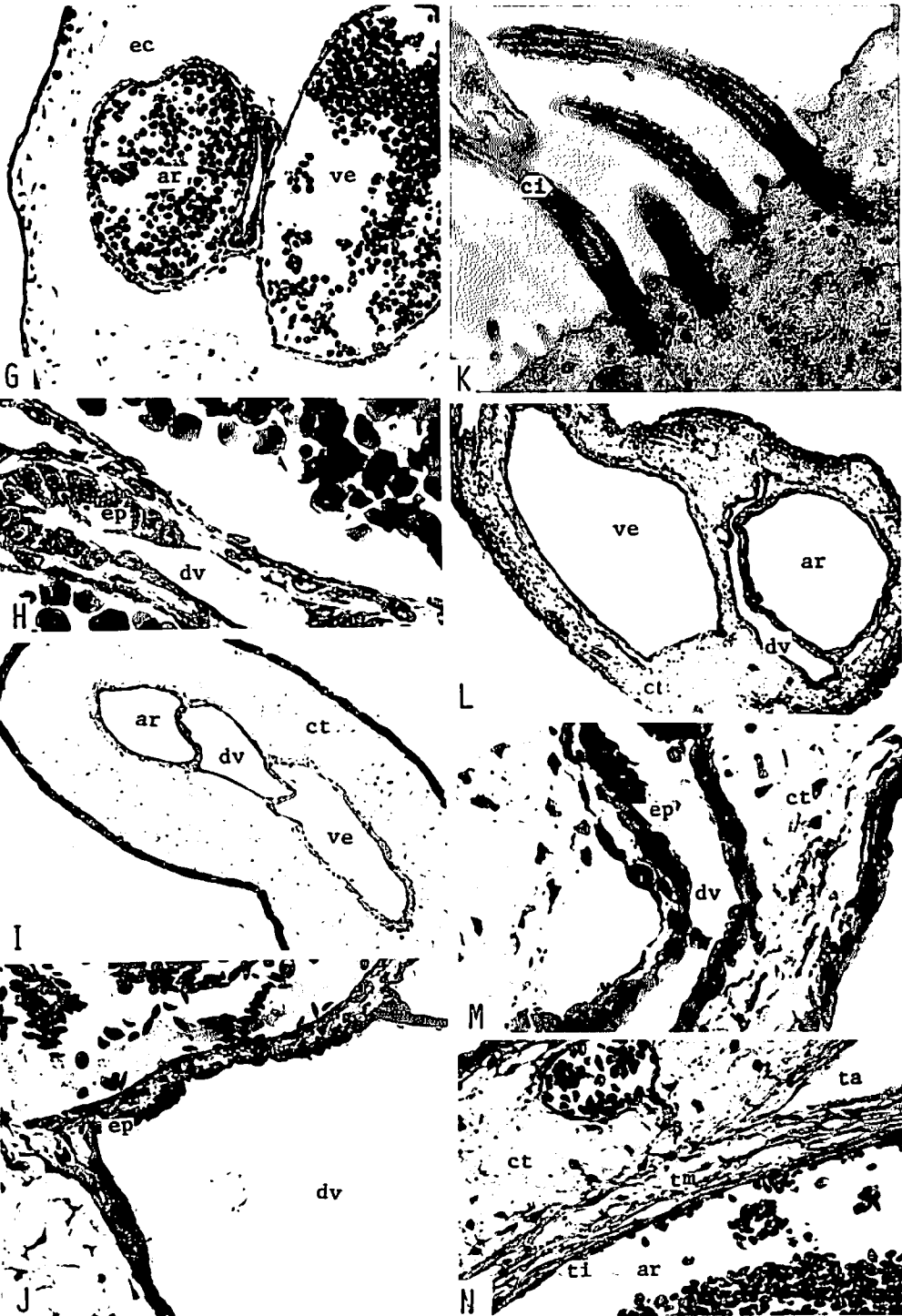
2.8.2. Epithelium of ductus vitellointestinalis

In *Mustelus manazo*, when the embryos are about 50mm in total length, the ductus vitellointestinalis is lined by a single layer of cuboidal (at the lateral portions) and squamous cells with relatively developed cilia (Fig. 18B). When the embryo is about 100mm in length, the ductus vitellointestinalis is covered with a simple

Fig. 18—II. Yolk stalk in *Mustelus manazo* and *M. griseus*.

- G. Transverse section of yolk stalk, embryo: 34 mm in total length. *M. griseus*, × 30.
- H. A partial magnification of G. Both cuboidal and squamous cells cover the internal surface of the ductus vitellointestinalis. × 200.
- I. Transverse section of yolk stalk, embryo: 98 mm. *M. griseus*, × 50.
- J. A partial magnification of I. The ductus vitellointestinalis. × 200.
- K. A partial magnification of J. Cilia are observed. × 19,800.
- L. Transverse section of umbilical stalk, embryo: 235 mm. *M. griseus*, × 20.
- M. A partial magnification of L. The epithelium of the ductus vitellointestinalis. × 200.
- N. A partial magnification of L. The wall of the umbilical artery consists of the tunica intima, tunica media and tunica adventitia. × 200.

ar: artery, ci: cilium, ct: connective tissue, dv: ductus vitellointestinalis, ec: extra-embryonic coelom, ep: epithelium, ta: tunica adventitia, ti: tunica intima, tm: tunica media, ve: vein.



ciliated cuboidal epithelium (Fig. 18D). When the embryos reach about 230mm in total length, the epithelium consists of a single layer of tall ciliated columnar cells (Fig. 18F). In *M. griseus*, there are no remarkable changes in the epithelium of the ductus vitellointestinalis throughout the embryonic development. The epithelium is mainly composed of squamous and cuboidal cells (Fig. 18H, J.M.). The cilia are not well developed and much reduced in number compared with *M. manazo*.

2.8.3. Consideration

In both *Mustelus manazo* and *M. griseus*, the ciliated epithelium undoubtedly aids in transport of the yolk to the intestine of the embryo.

The cilia and the epithelium of the ductus vitellointestinalis in *Mustelus manazo* are much more developed than those in *M. griseus*. Since the placenta is not formed in *M. manazo*, most of the nutrition for embryos depends upon the yolk, which is absorbed by the epithelium of the intestine. The well developed cilia aid in the efficient transportation of yolk.

The yolk (umbilical) stalks of the selachian can be divided into two types according to their external characteristics. The yolk stalk in the first type forms the special structures, called appendicula, on its sheath. The stalk in the second type has the smooth external surface without any structures. Appendiculae are present in species such as *Zygaena blochii*⁴⁸⁾, *Scoliodon sorrakowah*^{1,2)}, *S. palasorrah*¹⁾, *S. walbeehmi*¹⁾, *S. actus*³⁾, *S. terraenovae*⁴⁹⁾, *S. laticaudus*⁴⁷⁾, *Sphyrna tiburo*³⁶⁾ and *Carcharhinus* sp.⁵⁰⁾, and absent in species such as *Squalus acanthias*³⁸⁾, *M. canis*⁵¹⁾, *C. falciformis*³⁵⁾, *C. dussumieri*⁵⁰⁾, *M. manazo* and *M. griseus* of the present material.

The appendiculae are formed by a modification of the stalk sheath and are extensions of the extra-embryonic somato-

pleure. Various types of appendiculae have been known in accordance with their shape. The appendiculae appear to function in the absorption of the uterine secretions^{1,36,48,50)}. TEWINKEL⁵¹⁾, working with *Mustelus canis*, whose yolk stalk is of the smooth type, described that a brush border which is elaborated on the extensions of free surface cells of the stalk suggests a special function, i.e., the modified surface epithelium of the stalk absorbs nutrients from the uterine fluid.

External surface of the yolk (umbilical) stalk in *Mustelus manazo* and *M. griseus* is lined by simple epithelium. The external epithelium of the stalk consists of stratified epithelium in *Squalus acanthias*³⁸⁾, *M. canis*⁵¹⁾, *Carcharhinus falciformis*³⁵⁾ and *C. dussumieri*⁵⁰⁾.

The space occupied by the ductus vitellointestinalis in the stalk appears to be wider in the non-placental species than in the placental species.

2.9. Maturity

There are several methods for estimating the length at maturity of female sharks. In this study, occurrence of pregnancy and the size of ova in the ovary are used to determine the length at maturity.

Among the present specimens of *Mustelus manazo*, the smallest gravid female was 630mm in total length, and the largest immature female was 651mm in length. The immature female had ova of 9–10mm in diameter in its ovary. The posterior portions of the uteri were enlarged, but the anterior portions were still slender. In *M. griseus*, the smallest gravid female was 760mm in total length and the largest immature specimen found in the present investigation was 675mm in length. The immature female contained ova of 12–13mm in diameter in its ovary.

Consideration

The condition of uteri and ovary in the immature female of *Mustelus manazo* (651 mm in total length) suggested that this shark was approaching maturity. Hence, female *M. manazo* probably reaches maturity when it is 630–700 mm in total length. Since the diameter of the ovum at ovulation is about 15 mm in *M. griseus*, the immature female of *M. griseus* (675 mm in total length) seems to be reaching maturity. It is thus assumed that female *M. griseus* reaches the maturity between 680 and 760 mm in total length.

According to TESHIMA et al.²⁴⁾, female *Mustelus manazo* in the northern waters of the East China Sea reaches the maturity when it is between 620 and 640 mm in total length. HISAW and ABRAMOWITZ^{25,26)} indicated that female *M. canis* in the waters off Massachusetts becomes fully mature at a length between 95 and 100 cm. CLARK and VON SCHMIDT⁴³⁾, working with an extensive studies on sharks in the Central Gulf Coasts of Florida, mentioned that most *M. norrisi* specimens between 60 and 70 cm in length were mature, the female apparently maturing at a slight larger size.

TANAKA and MIZUE⁵²⁾ has investigated the growth and age of *Mustelus manazo* occurring in the northern East China Sea. According to the growth curve (relationship between total length and age) studied by them, female *M. manazo* of the present investigation is estimated to reach maturity when it is between two and three years old. The present female *M. manazo* thus appears to start reproductive activity when it reaches the total length between 630 and 700 mm and the age between two and three years.

3. The Male

The male reproductive organs in both *Mustelus manazo* and *M. griseus* consist of the testis, the epididymis, the spermiduct, the seminal vesicle and the clasper (Fig. 19). Spermatozoa, produced in the testis, pass through the epididymis and spermiduct and are stored in the seminal vesicle. During mating the spermatozoa are sent to the uterus through the clasper groove and fertilization takes place.

3.1. The testis and spermatogenesis

3.1.1. The testis

In both *Mustelus manazo* and *M. griseus*, the testis is formed at the anterior end of the epigonal organ. The epigonal organs form a pair and are suspended by thin membrane from the dorsal side of the peritoneal cavity. The epigonal organs, which exist in both sexes, show the same histology. They contain many capillaries and are filled with composed cells (Fig. 20A). When the shark is immature, the epigonal organs are small and slender. Their volume increases with the growth of the shark. As the shark reaches maturity, the testis is formed at the anterior end of the epigonal organ.

Testes of both *Mustelus manazo* and *M. griseus* have seminiferous tubules. The seminiferous tubules are supported by the interstitial cells (Fig. 20D). In both species spermatogenic cells, in various developmental stages, are observed in a cross section of the testis throughout the year (Fig. 20B).

3.1.2. Spermatogenesis

In both *Mustelus manazo* and *M. griseus*, the spermatogenic cells develop into the spermatozoa through the same process. In both species spermatogenesis is divided into two stages; 1) the first stage

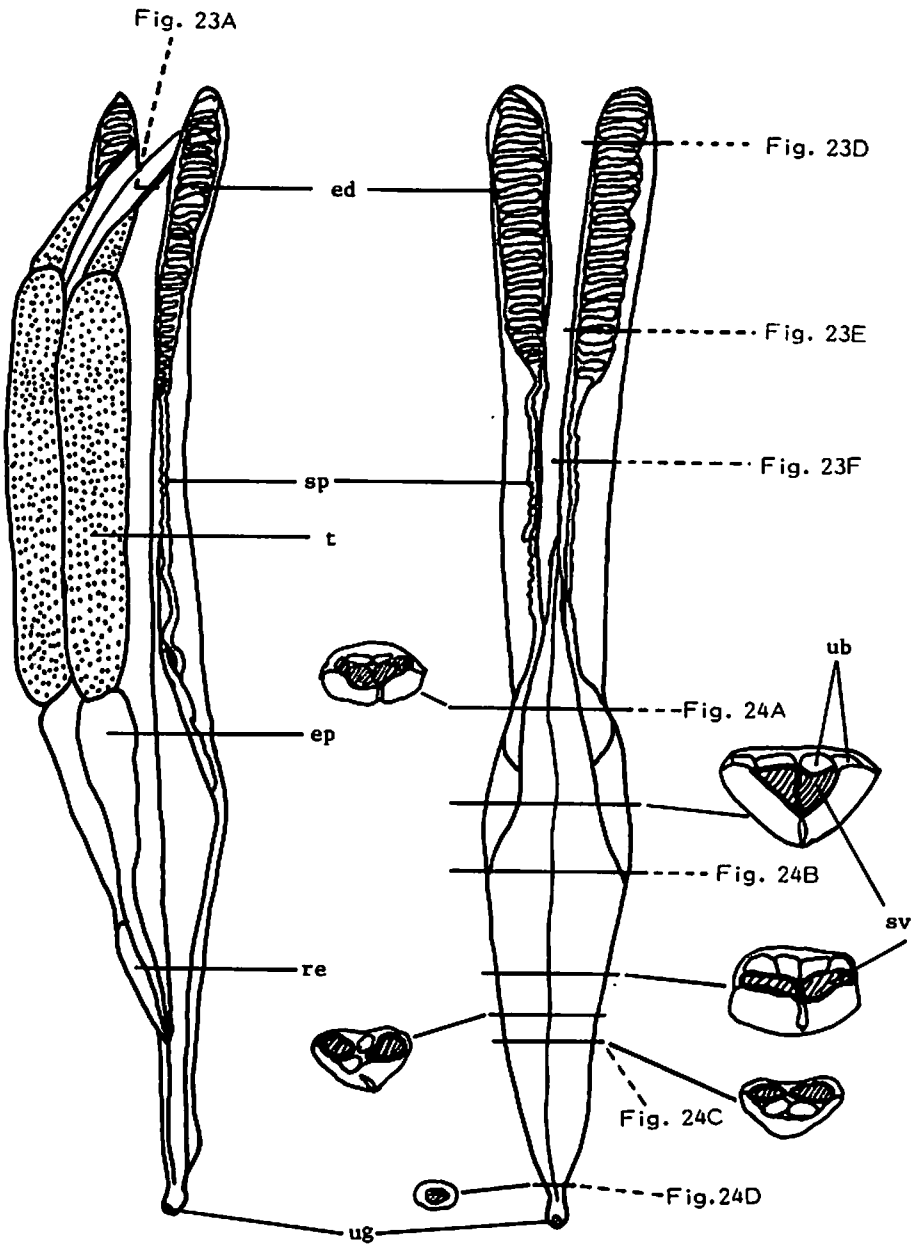


Fig. 19. Male reproductive organs in *Mustelus manazo* and *M. griseus*.
 ep: epigonal organ, ed: epididymis, re: rectal gland, sp: spermiduct, sv: seminal vesicle, t: testis, ub: urinary bladder, ug: urino-genital papilla.

is spermiocytogenesis where spermatogenic cells are repeatedly divided and become spermatids, and 2) the second stage is spermiotogenesis where the shape of the spermatid is transformed to become a spermatozoon.

3.1.2.1. Spermiocytogenesis

The internal surface of the seminiferous tubule in the early stage of spermatogenesis is lined with seminiferous epithelium. The seminiferous epithelium consists of a single layer of tall columnar cells. Spermatogonia are the most primitive spermatogenic cells and they appear between the seminiferous epithelium and the basement membrane of the seminiferous tubule (Fig. 20C). The spermatogonia proliferate and push the seminiferous epithelium towards the lumen (Fig. 20D). The seminiferous epithelial cells gradually disappear while they support the spermatogenic cells and provide them with nutrition. The seminiferous epithelial cells function as nurse cells. The spermatogonia repeatedly divide and develop into the spermatocytes (Fig. 20E). The spermatocytes are the largest spermatogenic cells. The nucleus lacks a resting period and is always active. The spermatocytes develop into the secondary spermatocytes by division (Fig. 20E). The secondary spermatocytes then become the spermatids by division (Fig. 20F). After this stage, no further division occurs.

3.1.2.2. Spermiotogenesis

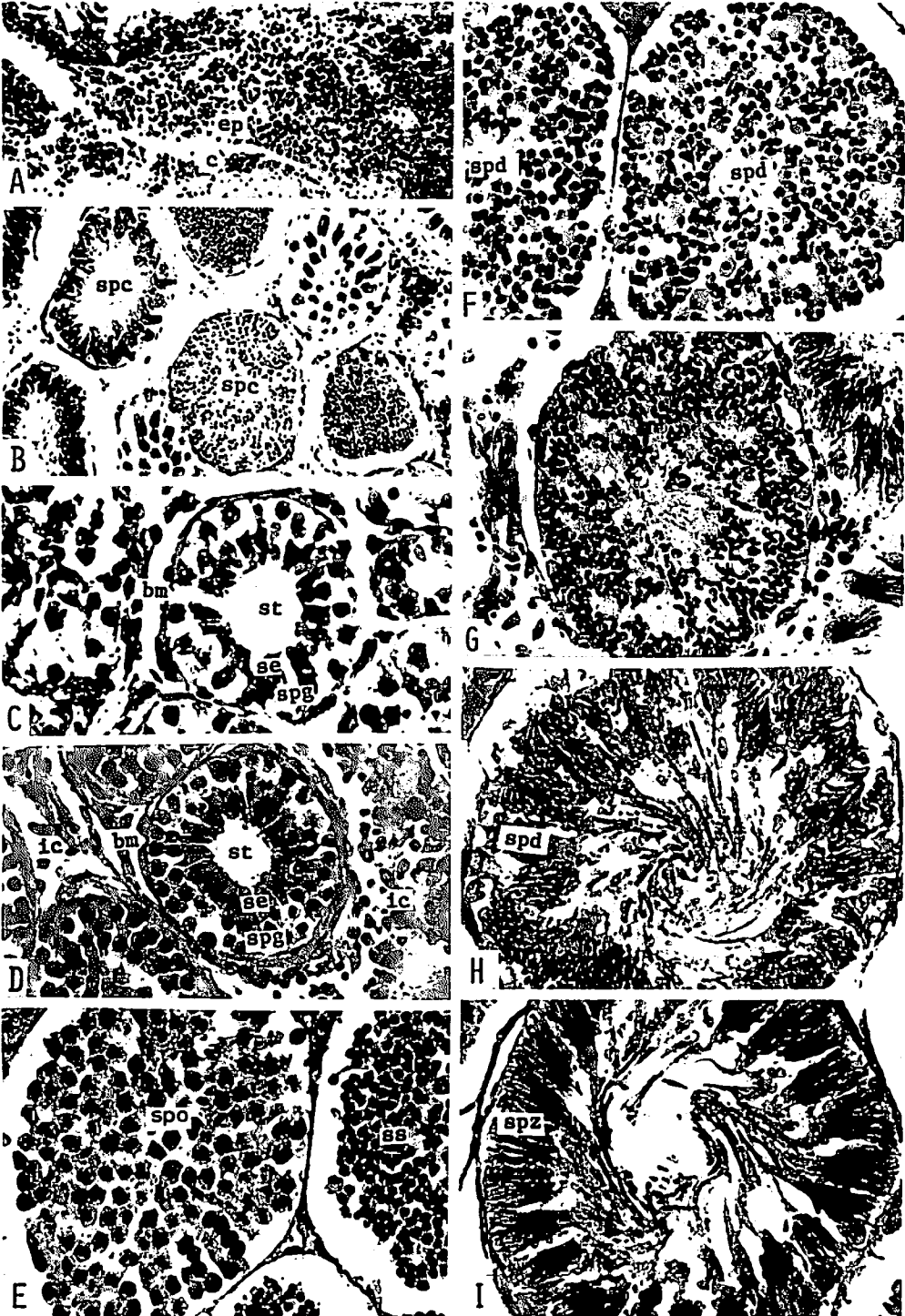
The spermatids undergo a shape transformation as they develop into spermatozoa. The nucleus becomes slender and forms the head of a spermatozoon while cytoplasm becomes the tail. As the spermatids develop into the spermatozoa, a group of about 60 spermatozoa each gather to form a sperm

clump. Each of spermatozoa is oriented with its head pointing towards the basement membrane of the seminiferous tubule and with its tail towards the center of lumen. The head of a spermatozoon becomes slender like a fiber, and spirals during development (Fig. 20Q).

Sperm clumps are formed during the transformation of spermatids. In both of *Mustelus manazo* and *M. griseus*, two types of clumps are observed. In the first type the spermatids, in the course of transformation, move towards the basement membrane of the seminiferous tubule (Fig. 20G, H). The spermatids are located along the basement membrane as they develop into the spermatozoa. The spermatozoa show the dense arrangement (Fig. 20I). As they develop further, about 60 spermatozoa begin to form a sperm clump (Fig. 20J), and the complete sperm clump is formed (Fig. 20K). This is the final stage of spermatogenesis. In the second type, the spermatids are divided into groups and develop into spermatozoa (Fig. 20L, M, N). Each of these groups forms a sperm clump, and all sperm clumps move towards the basement membrane of the seminiferous tubule (Fig. 20—O). Spermatozoa in a sperm clump become more densely arranged with further development (Fig. 20P), and spermatogenesis is completed (Fig. 20K).

3.1.3. Monthly change of the gonad index and spermatogenic cells

In order to examine the monthly change of the gonad index and spermatogenic cells, the male specimens of *Mustelus manazo* were collected monthly during the period from July, 1975 to May, 1976, and those of *M. griseus* from May, 1974 to May, 1975. The number of specimens investigated is 150 in *M. manazo* and 110 in *M. griseus*. Gonad index was calculated from the following formula,



$GI = W/TL^3 \times 10^6$ W: testis weight (g),
TL: total length (cm).

3.1.3.1. Monthly gonad index (Fig. 21)

The monthly gonad index shows the same trend in both *Mustelus manazo* and *M. griseus*. The value of the gonad index reaches the minimum in June to July and ascends after this. The value reaches the maximum in November to December and descends after this. The value of the gonad index varies between 30 and 80 in *M. manazo* and between 5 and 40 in *M. griseus*.

3.1.3.2. Monthly change of spermatogenic cells developing in the testis (Fig. 22)

In both *Mustelus manazo* and *M. griseus* spermatogonia, spermatocytes, spermatids and spermatozoa are found in the testes of all the specimens throughout the year. However, the composition of these spermatogenic cells is different by month. In both species the seminiferous tubules containing the spermatogonia exist in the ventral side of testis. The spermatogenic cells contained in the tubules change from spermatogonia to spermatocytes and

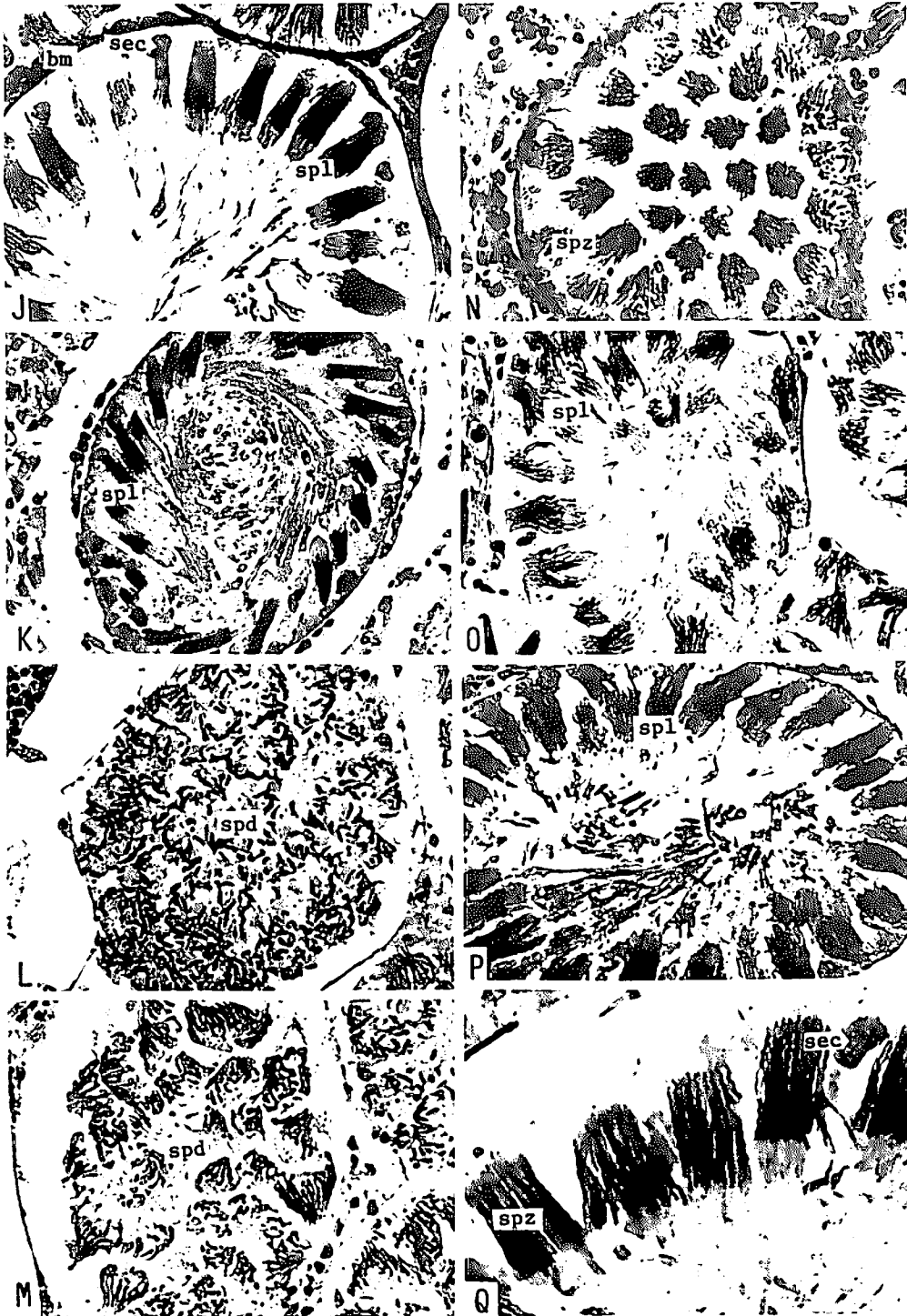
spermatids as they move towards to dorsal side; the seminiferous tubules containing the complete spermatozoa exist in the dorsal side of the testis. Within one seminiferous tubule, most spermatogenic cells are in the same developmental stage.

Fig. 22 indicates the monthly change of the occupying ratio of seminiferous tubules containing the spermatogenic cells in the various developmental stages in the transverse section of the middle portion of the testis. In both species a remarkable change is found in the occupying ratio of spermatocytes and spermatozoa throughout the year. Spermatogonia and spermatids show no significant change in their occupying ratio. When many spermatocytes are observed, the number of spermatozoa is small. On the other hand, when the number of spermatocytes developing is small, many spermatozoa are formed. In both species the occupying ratio of seminiferous tubules containing the spermatozoa is extremely low in July and August. In September, as the month advances, the spermatogenesis becomes vigorous. In December the number of seminiferous tubules containing spermatocytes, spermatids, and spermatozoa

Fig. 20—1. Spermatogenesis in *Mustelus manazo* and *M. griseus*.

- A. Epigonal organ. *M. manazo*, $\times 50$.
- B. Spermatogenic cells at various developmental stages are seen in a cross section of the testis. *M. manazo*, $\times 67$.
- C. Spermatogonia appear between the seminiferous epithelium and the basement membrane. *M. griseus*, $\times 268$.
- D. The seminiferous epithelium is pushed toward the lumen by the spermatogonia. *M. manazo*, $\times 200$.
- E. Spermatocytes (left seminiferous tubule) and the secondary spermatocytes (right). *M. griseus*, $\times 200$.
- F. Spermatids. *M. griseus*, $\times 200$.
- G. Spermatids, which are developing into spermatozoa, are moving toward the basement membrane of the seminiferous tubule. *M. griseus*, $\times 200$.
- H. Spermatids are arranged along the basement membrane. *M. manazo*, $\times 200$.
- I. Spermatozoa are densely arranged inside the basement membrane. *M. manazo*, $\times 200$.

bm: basement membrane, c: capillary, ep: epigonal organ, ic: interstitial cell, se: seminiferous epithelium, spc: spermatogenic cells, spd: spermatids, spg: spermatogonia, spo: spermatocytes, spz: spermatozoa, ss: secondary spermatocytes, st: seminiferous tubule.



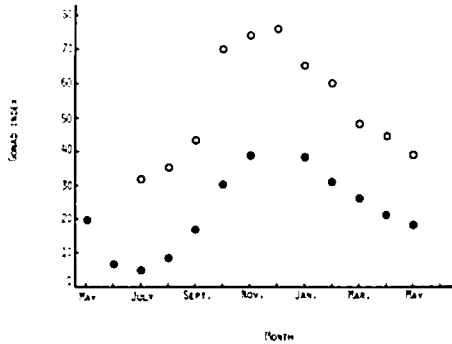


Fig. 21. Monthly change of the gonad index in *Mustelus manazo* (open circle) and *M. griseus* (closed circle).

becomes about equal. The occupying ratio of seminiferous tubules containing spermatozoa reaches the maximum by March in *Mustelus manazo* and May in *M. griseus*. In *M. manazo*, the number of seminiferous tubules containing the spermatozoa decreases during the period from April to June and the occupying ratio reaches the minimum in July and August. In *M. griseus*, it decreases rapidly in June and reaches the minimum in July and August.

Testes reach their yearly minimum in weight, length, and diameter in July and August, and increase in their size as the month advances after this. They reach their yearly maximum in December, and decrease after this.

3.1.3.3. Condition in the seminal vesicle

Both *Mustelus manazo* and *M. griseus* have the long spermiducts and seminal vesicles. The seminal vesicle is formed by an expansion of the posterior end of the spermiduct. Spermatozoa produced in the testis are accumulated in the seminal vesicle after passing through the spermiduct.

No spermatozoa are found in the spermiducts and the seminal vesicles of specimens in September and October. A small quantity of spermatozoa are found in those seminal vesicles examined in November and December. Spermatozoa in the seminal vesicles are accumulated after December, and the seminal vesicle becomes fully filled with spermatozoa by June. However, the seminal vesicles and spermiducts of specimens in July and August are either filled with spermatozoa or quite empty.

3.1.4 Consideration

It has been known that the testis of the teleost is divided into two types; the seminiferous tubular type and the lobular type⁵³⁾, and these two types also appear to be present in the selachian. The testis of *Mustelus manazo* and *M. griseus* consists of many seminiferous tubules and therefore belongs to the tubular type. According to MATTHEWS⁵⁾, the testis of *Cetorhinus*

Fig. 20—II. Spermatogenesis in *Mustelus manazo* and *M. griseus*.

- J. The formation of sperm clumps. The newly developed seminiferous epithelial cell is seen. *M. manazo*, × 50.
- K. The final stage of the spermatogenesis. *M. manazo*, × 200.
- L. Spermatids are divided into some groups where they develop into spermatozoa. *M. griseus*, × 200.
- M. Spermatids in each sperm clump develop into spermatozoa. *M. griseus*, × 200.
- N. Spermatids in each sperm clump develop into spermatozoa. *M. manazo*, × 200.
- O. Sperm clumps move toward the basement membrane. *M. griseus*, × 200.
- P. Spermatozoa in a sperm clump are densely arranged. *M. manazo*, × 200.
- Q. The head of spermatozoon is spiral. Newly developed seminiferous epithelial cell is seen near the basement membrane. *M. manazo*, × 200.

bm: basement membrane, sec: seminiferous epithelial cell, spd: spermatids, spl: sperm clump, spz: spermatozoa.

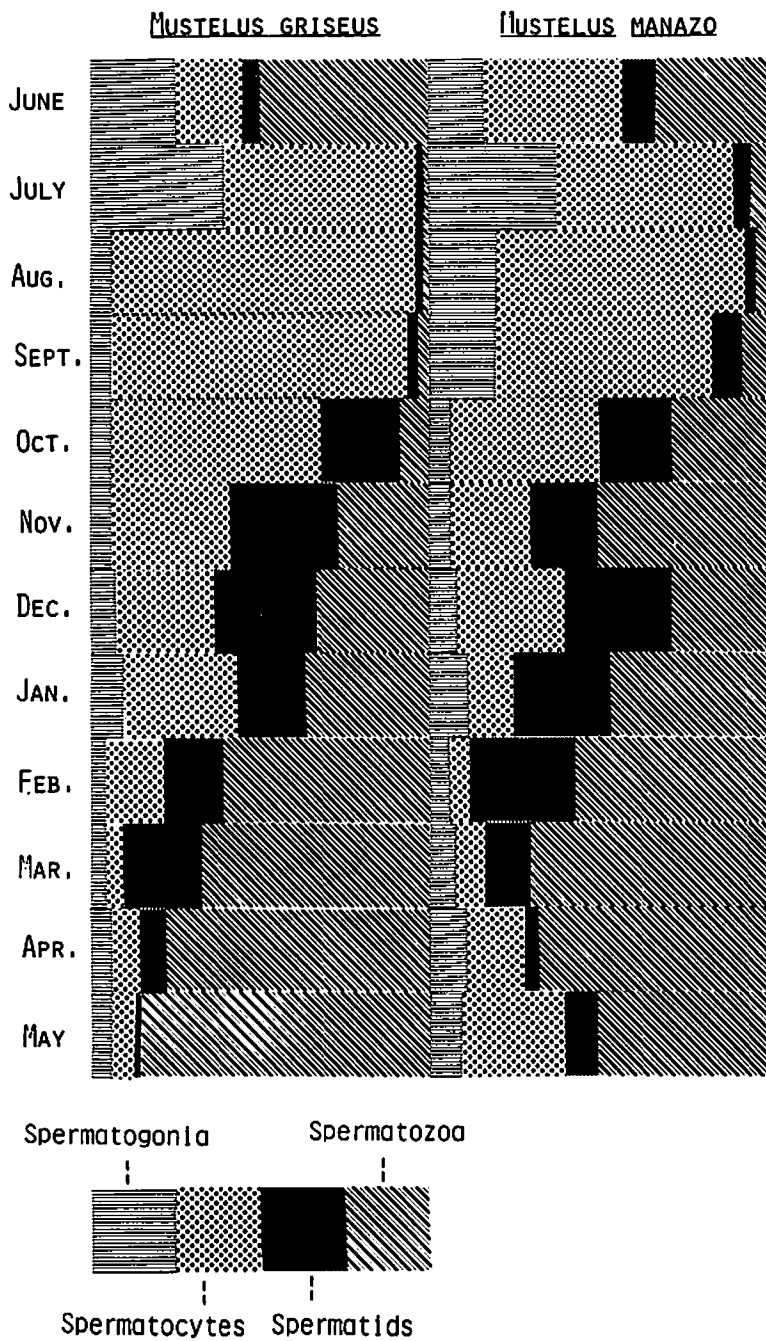


Fig. 22. Monthly change of spermatogenic cells in *Mustelus manazo* and *M. griseus*.

maximus is formed by many lobules and it is of the lobular type. Each of the testis is subdivided into lobules and each lobule consists of many closely packed ampullae. Spermatogenesis takes place in each ampulla. Each lobule is wedge-shaped and the apices of the wedges meet at the center of the lobe.

In *Mustelus manazo* and *M. griseus*, the seminiferous epithelium is located in the inside of the basement membrane of the seminiferous tubule. Spermatogonia appear between the basement membrane and the seminiferous epithelium. In *Cetorhinus maximus*, numerous "nest" of cells exist in the lobules⁷⁾. Each nest is surrounded by a very thin coating of flat investing cells which encloses a large central cell. The central cell increases in number by division to form a single layer of cells. An ampulla is formed in the space surrounded by a single layer of cells. This single layer of cells differentiates into two layers of cells. The inner cells are spermatogonia and the outer cells are spermatocytes. Spermatogonia thus originate in the central cell of the nest of cells in *C. maximus*. In *C. maximus*, therefore, spermatogonia are located in the inner side of spermatocytes within an ampulla while the spermatogonia exist in the outer side of the seminiferous epithelium within a seminiferous tubule in *M. manazo* and *M. griseus*.

According to MATTHEWS⁷⁾, Sertoli cells exist in the testis of *Cetorhinus maximus*. With development of spermatogenic cells, the ampulla is filled with spermatocytes, and the spermatogonia, surrounding the lumen, enter the layer of spermatocytes. The spermatogonia move towards the basement membrane of the ampulla and become the Sertoli cells. In *Mustelus manazo* and *M. griseus*, although the seminiferous epithelium is pushed towards the lumen with the development of

spermatogenic cells, part of the epithelial cells appear to function as the nurse cells which provide nutrition to the spermatogenic cells.

In *Mustelus manazo* and *M. griseus*, when the sperm clumps are formed, the heads of spermatozoa are spiral in shape. These also observed in *Cetorhinus maximus*⁷⁾, *Carcharhinus dussumieri*⁵⁴⁾, *Galeorhinus japonicus*⁵⁴⁾ and *Rhinobatus schlegeli*⁵⁴⁾. METTEN²⁷⁾, working with *Scylliorhynchus canicula*, reported that the head of spermatozoon is spiral in shape. According to MOORE⁵⁵⁾, however, the heads of spermatozoa in *Scyllium canicula* and *S. catulua* are not spiral but straight in shape.

In mammalian spermatogenic cells in the various developmental stages are observed in the same seminiferous tubule^{56,57)}. As far as has been investigated, in selachian, spermatogenic cells within the same seminiferous tubule, or within the same ampulla represent the same developmental stage.

Concerning the marine teleosts, YAMAMOTO⁵⁸⁾, working with *Liopsetta obscura* (HERZENSTEIN), and MIZUE^{53,59,60,61)}, with *Sebastes marmoratus* (CUVIER et VALENCIENNES), *Sabastes inermis* CUVIER et VALENCIENNES, and *Ditrema temmincki* BLEEKER, have described in detail the monthly changes of the gonad indices of these species. According to YAMAMOTO⁵⁸⁾ and MIZUE^{53,59,60,61)}, the discharge of spermatozoa in these species occurs when the value of the gonad index starts descending or is descending from the maximum.

In both *Mustelus manazo* and *M. griseus*, a time lag is found between the peak in the gonad index and the maximum in the occupying ratio of the seminiferous tubules containing the spermatozoa. The occupying ratio reaches the maximum four to five months later than the peak of the gonad index. However, this does not

indicate that the testis is most active when the occupying ratio of seminiferous tubules containing the spermatozoa reaches the maximum. Although the occupying ratio of spermatozoa increases during the period from December to April or May, the space occupied by seminiferous tubules containing the spermatozoa in the testis almost the same during this period due to reduction of testis weight, length and diameter. During the period from December to around April or May, when the value of the gonad index is descending, spermatozoa are thus produced vigorously and accumulated in the seminal vesicle.

The lag between peak in gonad index and spermatozoa discharge in *Mustelus manazo* and *M. griseus* (as compared to the teleosts described by YAMAMOTO and MIZUE, in which a peak in gonad index and spermatozoa discharge occur at the same time) is due to the structural differences in the reproductive systems. In both *M. manazo* and *M. griseus*, the spermatozoa produced are sent out of the testis when the value of the gonad index is descending. Due to the fact that both *M. manazo* and *M. griseus* have very long spermiducts and expanded seminal vesicles, spermatozoa sent out of the testis are not discharged out of the body immediately, but are accumulated in the seminal vesicle.

In the gonad index graph, when the value reaches the maximum, a small quantity of spermatozoa are found in the seminal vesicle. Conversely, the seminal vesicle becomes filled with spermatozoa, as the value reaches the minimum.

Spermatozoa are usually discharged when the testis activity is greatest in the teleosts^{53,59,60}, but the discharge of spermatozoa in both *Mustelus manazo* and *M. griseus* takes place when the testis activity is at its lowest.

No spermatozoa are found in the

spermiducts and the seminal vesicles in September and October. Additional to this, the seminal vesicle becomes fully filled with spermatozoa by June. These facts suggest that the spermatic fluid filling the seminal vesicle is discharged out of the body in June to August, i.e., mating in both species takes place in this period. In the gonad index graph, mating occurs when the value is minimum.

In both *Mustelus manazo* and *M. griseus* female, ovulation occurs in June and July^{22,62}. The ovulating season agrees with the mating season estimated by the monthly change of the gonad index and the condition of the seminal vesicle in *M. manazo* and *M. griseus*. Ovulation, mating and fertilization in Japanese *Mustelus* species thus take place during the period from June to August.

3.2. The spermiduct

Spermatozoa produced in the testis are accumulated in the seminal vesicle after passing through the epididymis and spermiduct. Both epididymis and spermiduct are located on the kidney. The posterior end of the long winding ductus epididymidis is continuous with the direct spermiduct. During copulation the spermatozoa filling the seminal vesicle are transported, through the clasper groove, into the uterus of female. The epididymis, spermiduct and seminal vesicle are histologically similar in *Mustelus manazo* and *M. griseus*.

3.2.1. Epididymis

Sperm clumps, formed in the testis, are sent through the seminiferous tubules to a slender duct situated in the dorsal side of the testis (Fig. 23A). This duct is connected with the epididymis. The internal surface of the duct is lined with a single layer of ciliated columnar cells.

External to the epithelium is a layer of the circular muscle fibers where large cells are scattered (Fig. 23B). The sperm clumps which pass through the duct are dissolved by secretion and transported to the epididymis.

The epididymis consists of a long winding ductus epididymidis which occupies 5 to 7 cm in direct length on the kidney. The internal surface of the ductus epididymidis is covered with pseudostratified epithelium of ciliated columnar cells (Fig. 23C). The internal epithelium of the ductus epididymidis has cells which are similar in height at the upper portion (Fig. 23D), but the epithelium at the lower portion consists of the cells of varying height forming uneven surface (Fig. 23E). External to the basement membrane is a layer of the circular smooth muscle fibers. The muscular coat at the upper portion is thicker than that at the lower.

3.2.2. Spermiduct

The wall of the spermiduct consists of the mucous membrane and the muscular coat. The mucous membrane has some longitudinal folds, the epithelium of which is lined by a single layer of columnar cells. Beneath the epithelium is the lamina propria mucosae with scattered blood vessels. The muscular coat is formed mainly by circular muscle fibers (Fig. 23F).

3.2.3. Seminal vesicle

The posterior portion of the spermiduct is modified to form the seminal vesicle as the shark reaches maturity. The seminal vesicle is situated between the urinary bladder and the kidney at the anterior and middle portions, but it is situated above the urinary bladder at the posterior portion. The wall of the seminal vesicle consists of the mucous membrane and the muscular coat.

3.2.3.1 Anterior portion (Fig. 24A)

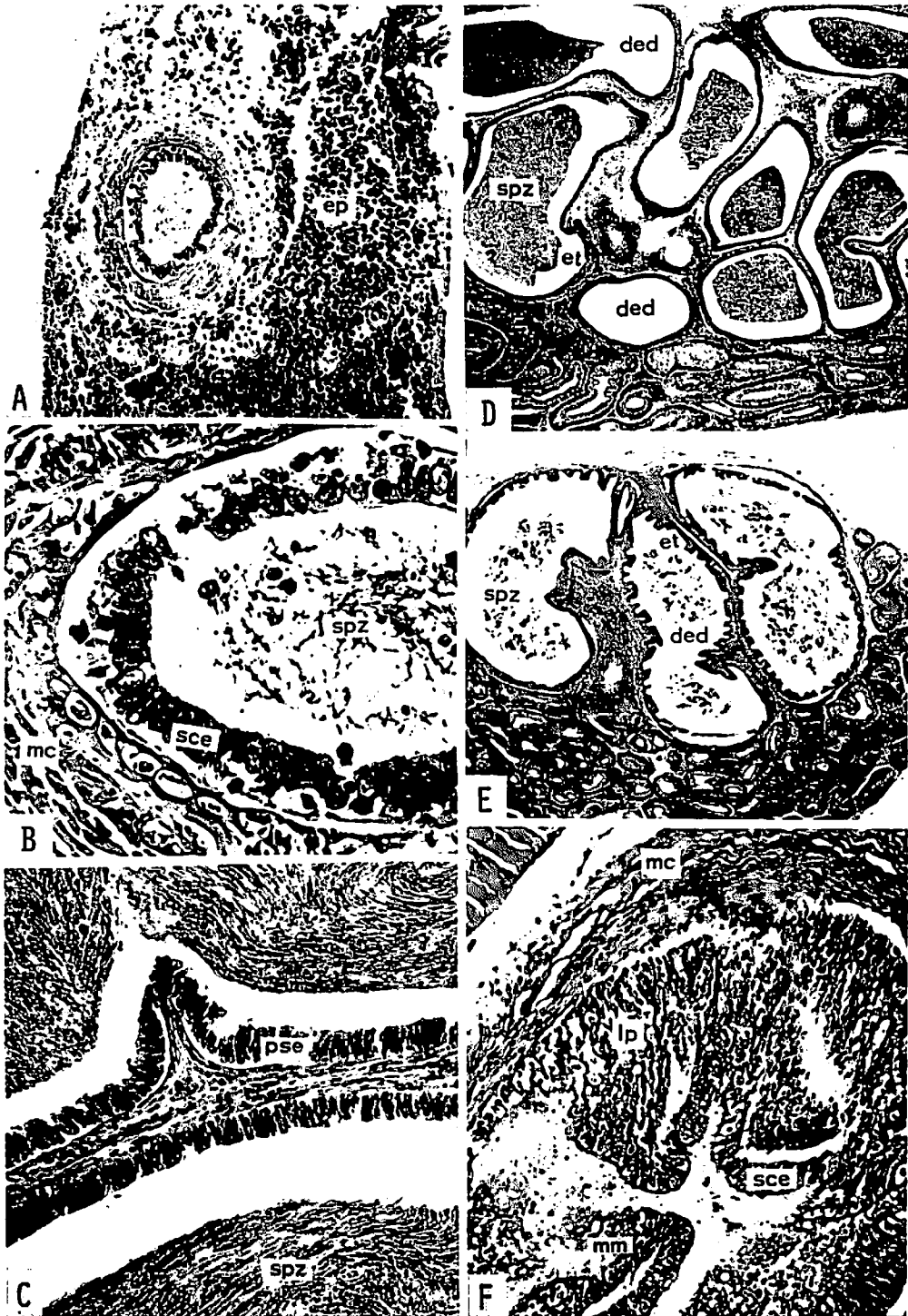
The seminal vesicle is divided into narrow compartments. The mucous membrane has many longitudinal folds protruding towards the lumen. The surface of the mucous membrane is covered with pseudostratified columnar epithelium. The epithelium lining the fold is a little thicker at the base of the fold. The lamina propria mucosae is very thin so that the epithelium attaches to the muscular coat in many places. The epithelium is ciliated. The muscular coat is mainly formed by circular muscle fibers, and longitudinal muscle fibers are scattered in the inner and outer sides of the layer of the circular muscle fibers (Fig. 24E).

Two urinary bladders are situated above the seminal vesicle. The internal surface of the urinary bladder is lined by a single layer of squamous or cuboidal cells. External to the epithelium is a layer of the circular muscle fibers (Fig. 24F).

3.2.3.2. Middle portion (Fig. 24B)

The middle portion of the lumen of the seminal vesicle is wider than that at the upper, but the number of compartments is reduced. Folds in the mucous membrane are smaller in number but longer than those of the upper portion. Although the mucous membrane is mainly lined by the pseudostratified columnar epithelium, stratified columnar epithelium covers some places. The epithelial cells have long cilia. The lamina propria mucosae is very thin, and the epithelium abuts against the muscular coat in many places. The muscular coat consists of circular and indistinct longitudinal muscle fibers (Fig. 24G).

The middle portion of the lumen of urinary bladder is wider than that of the upper. The internal surface of the bladder is covered with the stratified cuboidal epithelium. Beneath the



epithelium is the connective tissue composed of circular muscle fibers (Fig. 24H).

3.2.3.3. Posterior portion (Fig. 24C)

Both the seminal vesicle and the urinary bladder at this portion are at their maximum in size. In this section the position of the seminal vesicle and the urinary bladder changes, i.e., the seminal vesicle becomes situated above the urinary bladder (Fig. 24C).

The mucous membrane of the seminal vesicle is lined with pseudostratified columnar epithelium. Stratified cuboidal epithelium is found in some places. The lamina propria mucosae is thin and is absent in many places. The muscular coat is formed mainly by the circular muscle fibers in which longitudinal fibers are scattered (Fig. 24—I).

The internal surface of the urinary bladder is lined by two to three layers of cuboidal cells. Beneath the epithelium is the connective tissue composed of circular muscle fibers and blood vessels (Fig. 24—I).

3.2.3.4. Portion near urino-genital papilla (Fig. 24D)

In this section both seminal vesicle and urinary bladder are modified to form a single duct. Some folds are formed in the internal surface of the duct and the internal surface is covered with two to three

layers of cuboidal cells. Beneath the epithelium is a thick fibrous connective tissue containing many blood vessels. External to this is the muscular coat consisting of inner circular and outer longitudinal muscle fibers. The layer of the circular muscle fibers is thicker than that of the longitudinal (Fig. 24J).

3.2.4. Consideration

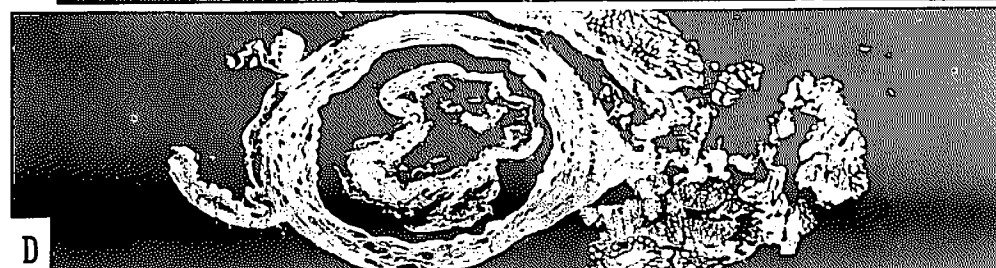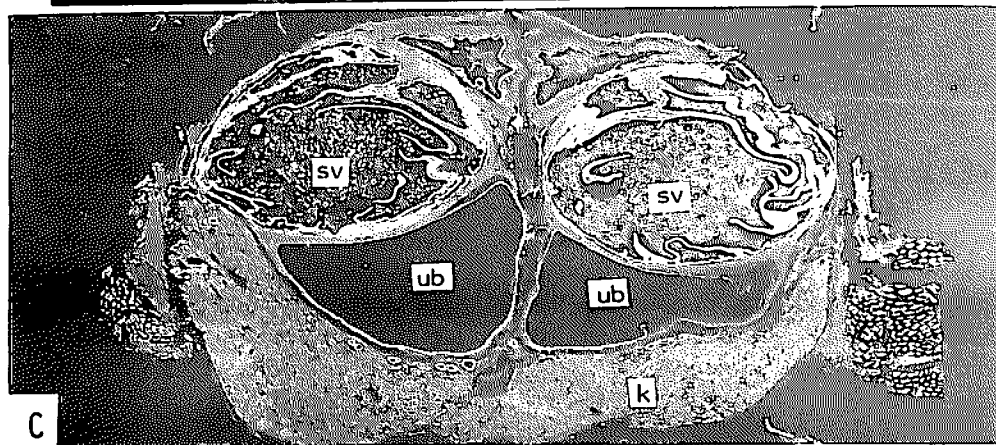
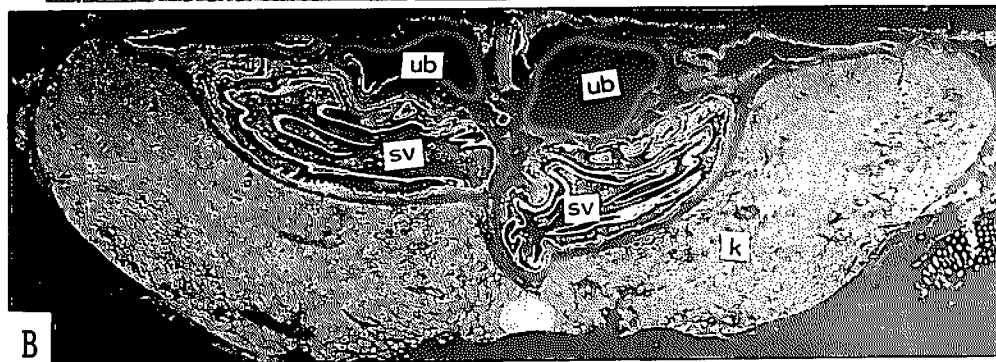
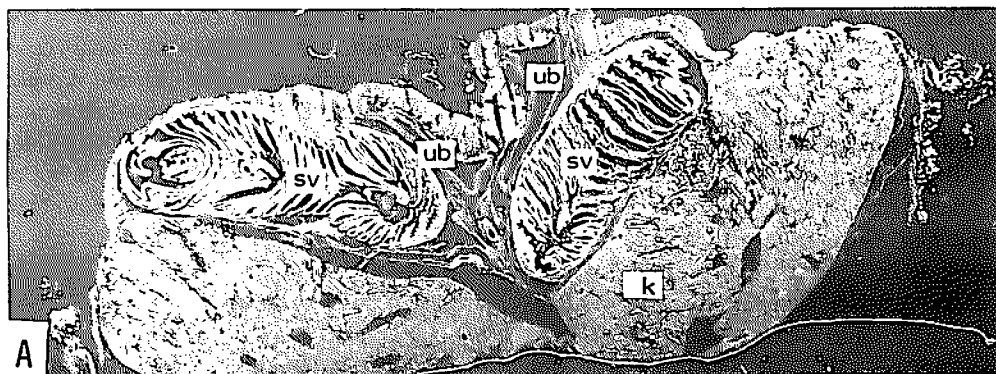
MATTHEWS⁷⁾, working with *Cetorhinus maximus*, stated that the internal surface of the ductus epididymidis is lined by a pseudostratified epithelium composed of tall columnar cells and that in the lower part of the epididymis the epithelium is raised into widely separated folds. These observations are similar to those made on the epididymis in *Mustelus manazo* and *M. griseus*.

In both *Mustelus manazo* and *M. griseus*, the seminal vesicle is fusiform in shape. The structure of the seminal vesicle is almost the same, histologically, at its upper, middle and lower portions in both species, i.e., the epithelium of the mucous membrane consists of pseudostratified columnar cells. The lamina propria mucosae is very thin. The muscular coat is mainly composed of circular muscle fibers. The posterior portion of the vesicle is large, and a portion about 2 to 3 cm anteriorly from the urino-genital papilla reaches the maximum in size. The mucous membrane folds, formed at the

Fig. 23. Epididymis and spermiduct in *Mustelus manazo* and *M. griseus*.

- A. A duct which transports spermatozoa from seminiferous tubules to epididymis. *M. manazo*, × 50.
- B. A partial magnification of A, × 200.
- C. A ductus epididymidis. *M. manazo*, × 50.
- D. A upper portion of the epididymis. *M. manazo*, × 10.
- E. A lower portion of the epididymis. *M. manazo*, × 10.
- F. Spermiduct. *M. griseus*, × 50.

ded: ductus epididymidis, ep: epigonal organ, et: epithelium, lp: lamina propria mucosae, mc: muscular coat, mm: mucous membrane, pse: pseudostratified epithelium, sce: simple columnar epithelium, spz: spermatozoa.



upper portion, are well developed compared with the lower portion. The wall of the seminal vesicle of *M. manazo* is thinner than that of *M. griseus*.

MATTHEWS⁷⁾ suggested that the ampulla of the ductus deferens is often incorrectly termed the "vesicula seminalis". In *Mustelus manazo* and *M. griseus* it may be, however, much better to use the term of seminal vesicle to refer to the expanded posterior portion of the spermiduct, because spermatozoa are accumulated in the expanded portion till the mating season (as was described in the change of the gonad index). In *Galeorhinus japonicus*, the seminal vesicle similar to that found in *M. manazo* and *M. griseus* is also formed⁵⁴⁾.

At the section near the urino-genital papilla only a single duct exists. The muscular coat of this duct is well developed compared to that of the seminal vesicle. The well developed muscular coat may expand and contract to push spermatozoa out of the urino-genital papilla during mating.

The histological structure of the wall near the urino-genital papilla of *Mustelus manazo* and *M. griseus* is similar to that of the copulatory organ of *Sebastiscus marmoratus* and *Sebastes inermis* where the circular and longitudinal muscle fibers are well developed.⁶³⁾

3.3. The clasper

The clasper is the copulatory organ and is formed by a modification of the pelvic fin, i.e., the cartilage is extended from the posterior end of the pelvic fin toward the caudal fin to form the clasper. In mating,

spermatozoa pushed out of the urino-genital papilla of the male, are conveyed into the uterus of the female through the clasper groove. Claspers form pairs.

3.3.1. Pelvic fin and clasper skeleton

Skeletons of the pelvic fin and clasper in *Mustelus manazo* and *M. griseus* are shown in Fig. 25.

The pelvic fin skeleton consists of the metapterygium, propterygium and radial cartilages. The propterygium is attached to the distal end of the pelvic girdle, and radial cartilages are attached to the metapterygium. The right and left metapterygium are supported by the pelvic girdle. In both *Mustelus manazo* and *M. griseus*, with the exception of the posterior five radial cartilages, each radial cartilage consists of two elements, a long, straight, proximal segment and a short, curved, distal segment with a sharp end. The propterygium is also made up of two elements.


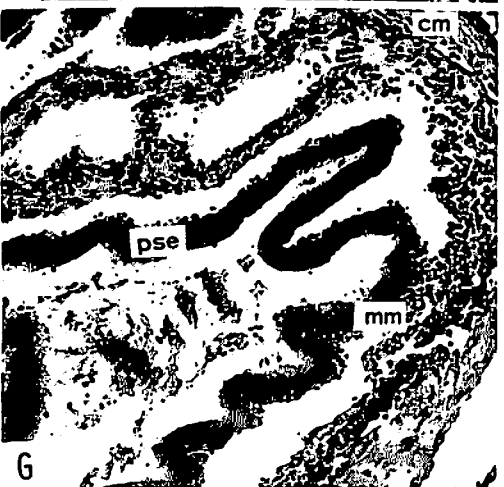
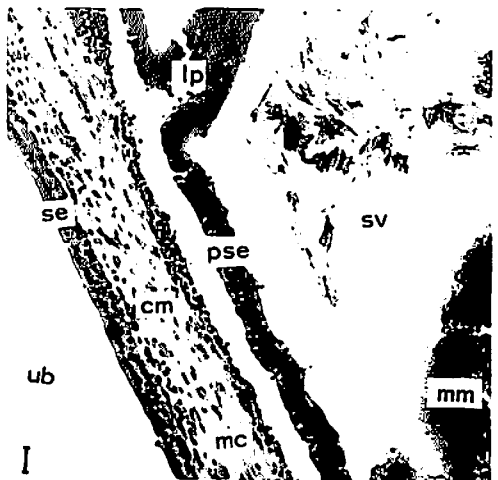
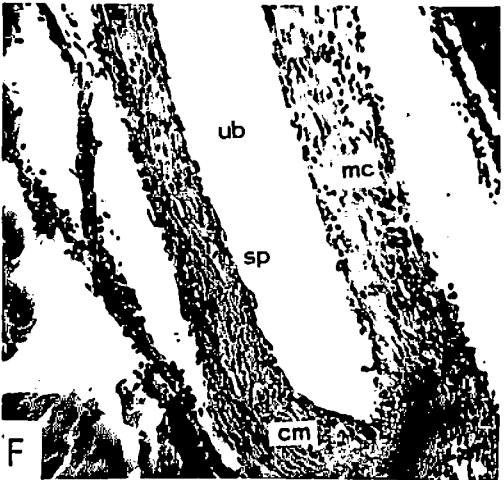
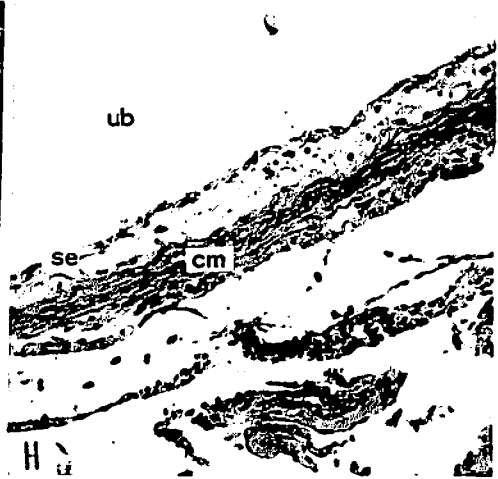
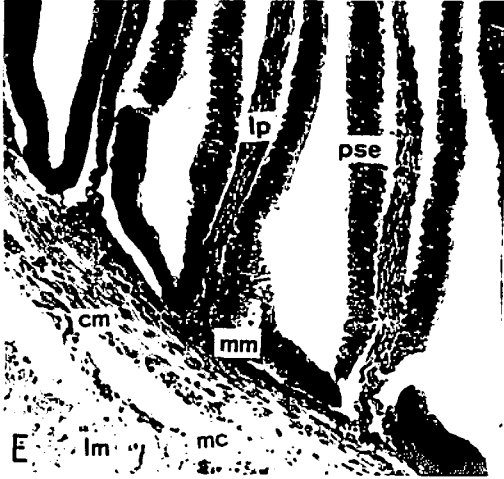
In the 19 specimens in *Mustelus manazo* examined, the number of the radial cartilages, which are attached to each metapterygium, ranged between 16 and 18 (11 specimens had 17). In *M. griseus*, the number of the radial cartilages of the 12 specimens examined varied from 15 to 16 (seven specimens had 16)

The clasper is attached to the metapterygium by means of the joint and beta cartilages. The clasper proper is made up of the main stem cartilage, six terminal cartilages and three groups of accessory cartilages. The elements composing the distal portion of the clasper are the inner terminal cartilage, the outer terminal

Fig. 24—I. Seminal vesicle in *Mustelus manazo*.

- A. Transverse section of the upper portion.
- B. Transverse section of the middle portion.
- C. Transverse section of the lower portion.
- D. Transverse section near urino-genital papilla.

k: kidney, sv: seminal vesicle, ub: urinary bladder



cartilage, 1st dorsal terminal cartilage, 2nd dorsal terminal cartilage, 3rd dorsal terminal cartilage, ventral terminal cartilage, dorsal accessory cartilage, 1st ventral accessory cartilage and 2nd ventral accessory cartilage. In *Mustelus manazo*, the 1st and 2nd ventral accessory cartilages are not found.

In both *Mustelus manazo* and *M. griseus*, a groove is formed on the dorsal side of the stem cartilage. This is called "clasper groove". A groove is also formed on the dorsal side of the inner terminal cartilage in both species. Although such a groove is formed on the dorsal side of the outer terminal cartilage in *M. griseus*, this groove is not found on the dorsal side of the outer terminal cartilage of *M. manazo*. In both species, each of the inner and outer terminal cartilages has a sharp distal end. The 1st, 2nd and 3rd dorsal terminal cartilages are positioned on top of one another as indicated in Fig. 25. In *M. manazo*, of elements consisting the dorsal accessory cartilage, the upper one is longer than the 1st dorsal terminal cartilage. In *M. griseus*, the dorsal accessory cartilage consists of some small segments. The ventral terminal cartilage has an elliptical shape in both species and it is attached to a protruding portion of the posterior end of the stem cartilage. The 1st and 2nd ventral accessory cartilages are not found in *M. manazo*. In *M. griseus*, the 1st ventral accessory cartilage consists

of five to eight minute segments, and the 2nd one consists of one or two small segments.

In *Mustelus manazo* and *M. griseus*, the relative lengths of the inner and outer terminal cartilages, the inner terminal cartilage and the clasper, and the outer terminal cartilage and the clasper are shown in Fig. 26. It becomes clear from this figure that; in *M. manazo*, the inner terminal cartilage is as long as the outer terminal cartilage. In *M. griseus*, the inner terminal cartilage is markedly longer than the outer terminal cartilage (Fig. 26A). The relative lengths of the inner and outer terminal cartilages to the clasper are 26.0% and 26.9% in *M. manazo*, and 20.1% and 16.4% in *M. griseus* (Fig. 26B, C).

Although the skeleton of the pelvic fin and the clasper is cartilage, it is relatively well stained with arizarinsulfonate. In particular, the pelvic girdle, the metapterygium, propterygium and the radial cartilages are well stained. The protruding portion of the posterior end of the stem cartilage, the dorsal side of the stem and the terminal cartilages are relatively well stained. The ventral side of the stem cartilage is not well stained (Fig. 27A).

3.3.2. Clasper action

In both *Mustelus manazo* and *M. griseus*, the right and left claspers are flexed forward at the portion of the joint cartilage.

Fig. 24—II. Seminal vesicle in *Mustelus manazo*.

- E. A partial magnification of the seminal vesicle of A, $\times 50$.
- F. A partial magnification of the urinary bladder of A, $\times 50$.
- G. A partial magnification of the seminal vesicle of B, $\times 50$.
- H. A partial magnification of the urinary bladder of B, $\times 50$.
- I. A partial magnification of C, $\times 50$.
- J. A partial magnification of D, $\times 50$.

bv: blood vessel, cm: circular muscle fibers, lm: longitudinal muscle fibers, lp: lamina propria mucosae, mc: muscular coat, mm: mucous membrane, pse: pseudostratified epithelium, se: stratified epithelium, sp: simple epithelium, sv: seminal vesicle, ub: urinary bladder.

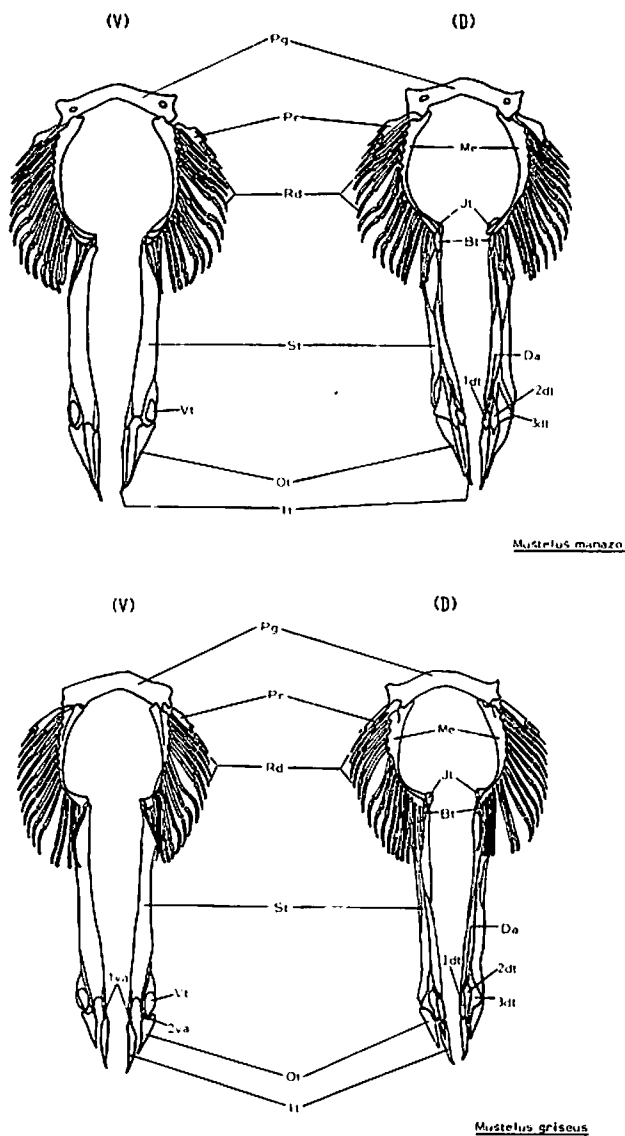


Fig. 25. Clasper skeleton in *Mustelus manazo* (upper) and *M. griseus* (lower).

D: dorsal side, V: ventral side.

1dt: 1st dorsal terminal cartilage, 2dt: 2nd dorsal terminal cartilage, 3dt: 3rd dorsal terminal cartilage, 1va: 1st ventral accessory cartilage, 2va: 2nd ventral accessory cartilage, Bt: beta cartilage, Da: dorsal accessory cartilage, It: inner terminal cartilage, Jt: joint cartilage, Me: metapterygium, Ot: outer terminal cartilage, Pg: pelvic girdle, Pr: propterygium, Rd: radial cartilage, St: stem cartilage, Vt: ventral terminal cartilage.

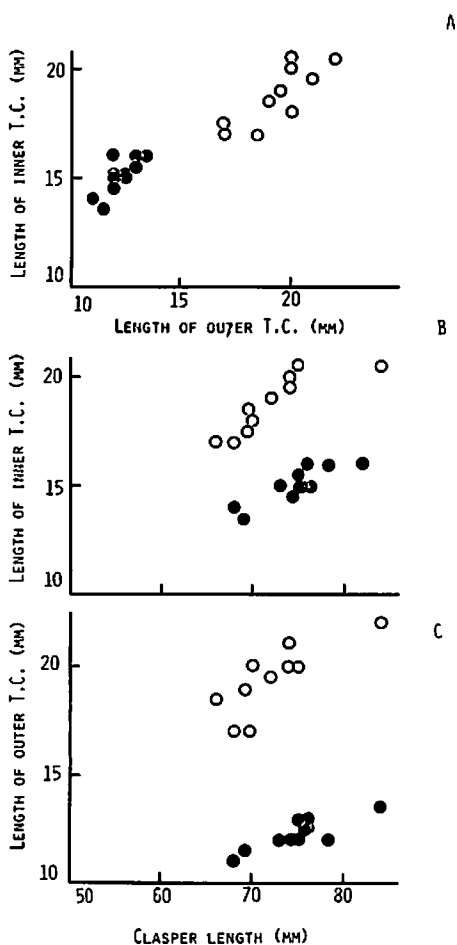


Fig. 26.
 A. Relationship between the inner and the outer terminal cartilage lengths in *Mustelus manazo* (open circle) and *M. griseus* (closed circle).
 B. Relationship between the inner terminal cartilage length and the clasper length in *M. manazo* (open circle) and *M. griseus* (closed circle).
 C. Relationship between the outer terminal cartilage length and the clasper length in *M. manazo* (open circle) and *M. griseus* (closed circle).

The clasper can be artificially bent forward 180° from its original position (Fig. 27C), but the real action of the clasper is not known in both *M. manazo* and *M. griseus*. The inner and outer terminal cartilages forming the distal portion of the clasper are flexed toward the ventral side (Fig. 27D). This action seems to be functional when the shark mates.

3.3.3. Consideration

It is not easy to distinguish the clasper of *Mustelus manazo* from that of *M. griseus* by their external characteristics because the claspers in both species are very similar each other. Differences are, however, observed in the pelvic fin and clasper skeleton of both species. The number of the radial cartilages of the pelvic fin ranges from 16 to 18, with a mode of 17 in *M. manazo*, but it varies between 15 and 16, with a mode of 16 in *M. griseus*. The number of the radial cartilages may be one of good characteristics in classifying both species. One more decisive difference is that; in *M. manazo*, the inner terminal cartilage is almost as long as the outer terminal cartilage while in *M. griseus*, the inner terminal cartilage is clearly longer than the outer terminal cartilage. In the relative lengths of the inner and the outer terminal cartilages to the clasper length, *M. manazo* have the higher percentage than *M. griseus*. The difference of length in the terminal cartilage thus may become an important characteristic in separating two species. According to ISHIYAMA⁶⁴, claspers of the Japanese rajid fishes are dividid into two types based on their structural differences between the northern and the southern forms. Furthermore, claspers of the northern forms are divided into seven subtypes and those of the southern forms are separated into six subtypes based on the

structural differences of cartilages composing the distal portion of the clasper. ISHIYAMA⁽⁶⁴⁾ has used these structural differences of the claspers as one of characteristics in classifying the Japanese rajid fishes.

In both *Mustelus manazo* and *M. griseus*, the clasper is rotated medially and then forward at the joint cartilage, and the inner and the outer terminal cartilages are also flexed toward the ventral side. This action seems to occur during mating. When the shark mates, it is considered that spermatozoa, pushed out of the urino-genital papilla, are transported through the clasper groove into the uterus of the female. There is, however, no connection between the urino-genital papilla and the clasper groove. It is therefore impossible for spermatozoa, pushed out of the urino-genital papilla, to enter the clasper groove as long as the clasper is in its original position. If the clasper is bent forward 180° from its original position, the urino-genital papilla can be plunged into the clasper groove near the root of the clasper. While the male keeps the clasper in this position, spermatozoa can be firmly sent into the clasper groove. It is therefore considered that during mating the male flexes the clasper forward 180° from its original position and inserts it into the uterus of the female. After insertion of the clasper, the inner and the outer terminal cartilages are flexed. This action of the terminal pieces appears to fix the clasper and prevent it from slipping out of the uterus.

Up to the present day mating behavior

has been reported on only two species of sharks. These are *Scyliorhinus canicula* and *Heterodontus francisci*. Concerning *S. canicula*, BOLAU⁽⁶⁵⁾, using the line drawing, and SCHENSKY⁽⁶⁶⁾ and HARDY⁽⁶⁷⁾ by photograph, have reported its mating behavior. The act of mating in *H. francisci* has been illustrated in a drawing by DEMPSTER and HERALD⁽⁶⁸⁾.

In *Scyliorhinus canicula* the male curls around the pelvic region of the female during mating. In *Heterodontus francisci* the mating position is different from *S. canicula*. In this case female lies on her left side facing the male during copulation. In both species only one clasper is thrust into the vent of female. *H. francisci* uses only the right clasper in its sexual act.


Neither *Mustelus manazo* and *M. griseus* has ever been observed during copulation, and the mating position in these species is not known.

Sharks have two uteri, and in the viviparous species both uteri usually contain embryos during gestation (except a few cases). It is an interesting problem to explain how the spermatozoa are transported into the right and left uterus simultaneously.


Morphological characters of the clasper skeleton are different depending on species. In *Mustelus manazo* and *M. griseus* the distal portion of the clasper is made up of six pieces of terminal cartilage. The distal portion of the clasper consists of two terminal cartilages in *Chlamydoselachus anguineus*⁽⁶⁹⁾ and four terminal cartilages in *Cetorhinus maximus*⁽⁷⁾ and *Squalus acanithias*⁽⁷⁰⁾. In these species

Fig. 27-1. Clasper and siphon sac in *Mustelus manazo* and *M. griseus*.

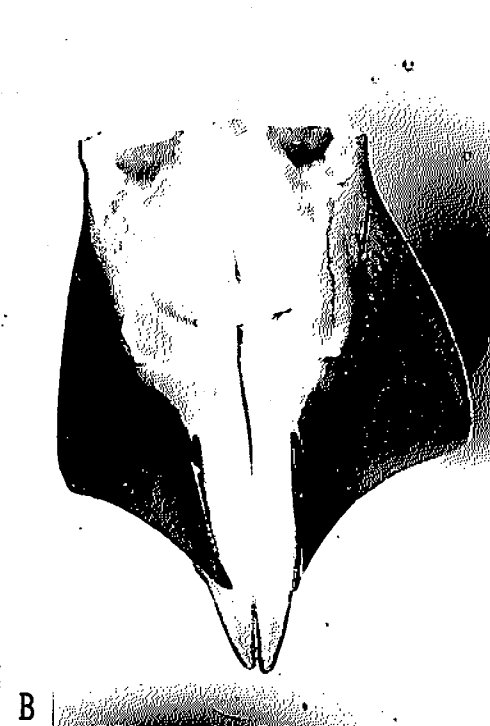- A. Clasper of a mature specimen in transparent condition, *M. manazo*.
- B. Clasper of an immature specimen in transparent condition, *M. manazo*.
- C. Clasper which is flexed forward, *M. griseus*.
- D. Distal portion of the clasper, which is flexed, *M. griseus*.




A



C



B



D

the number, size and shape of the terminal cartilages are different by species.

In both *Mustelus manazo* and *M. griseus* the skeleton of pelvic fin is already formed when the shark is immature. The number of radial cartilages in the immature shark is the same as that of the mature individual (Fig. 27A, B).

In the immature specimens of both *Mustelus manazo* and *M. griseus*, a very thin, slender tissue extends from the distal end of the metapterygium (Fig. 27F). This is not stained with arizarinsulfonate (Fig. 27B). This tissue is therefore considered to be the original tissue that will develop into a stem cartilage.

Of the *Mustelus manazo* specimens examined in the present investigation, the smallest specimen with a completely formed clasper was 652mm in total length. Another specimen was found in which the stem cartilage was still in the original condition, but the inner and the outer terminal cartilages were already formed. This specimen was 623mm in total length. In addition to these two, in a third specimen a portion of the cartilage that will develop into the inner terminal cartilage was made visible by staining with arizarinsulfonate. The total length of this specimen was 619mm. These facts suggest that in *M. manazo* the inner and outer terminal cartilages are first formed when the shark is about 620mm in total length, and the other terminal elements and the stem cartilage are rapidly formed before the shark reaches the total length of 650mm. The clasper skeleton in

M. manazo is thus completely formed when the shark is about 620 to 650mm in total length. The clasper skeleton in *M. griseus* appears to be formed at the total length between 720 and 750mm.

3.4. The siphon sac

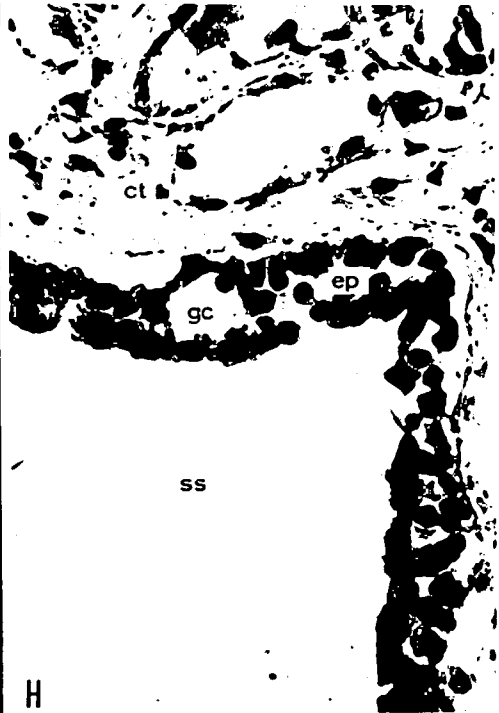
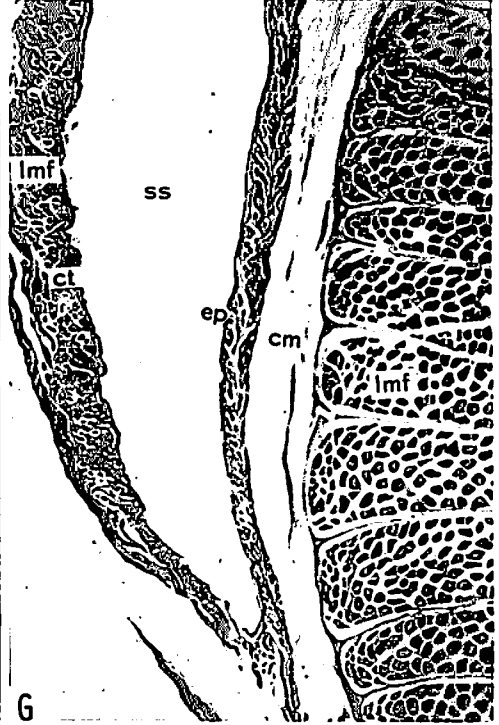
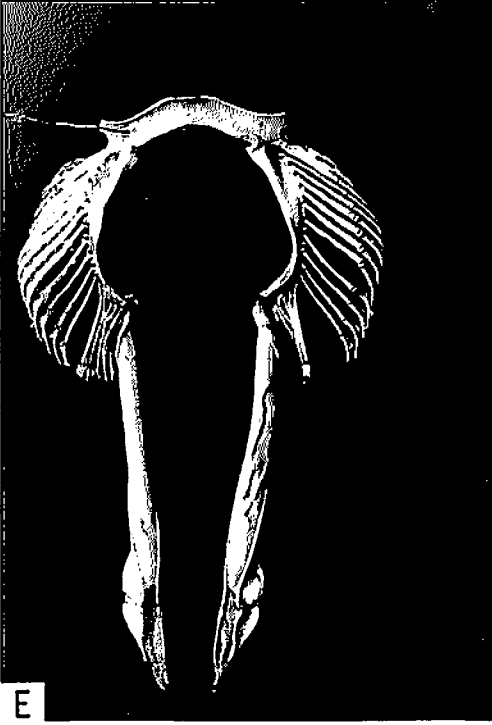The male of *Mustelus manazo* and *M. griseus* has a siphon sac. The siphon sac is formed as a slender cavity in the hypaxial musculature of the ventral region, and this is divided at the center into two compartments (Fig. 28A). In both species the anterior end of each sac ends blindly near the pectoral fin and the posterior end opens into the clasper groove.

The siphon sac in *Mustelus manazo* and *M. griseus* has the same histology. The internal surface is lined by two to three layers of cuboidal or polygonal cells with large, spherical nuclei, and goblet-like cells which scatter in some places (Fig. 27H). Beneath the epithelium there is fibrous connective tissue. External to this are many longitudinal bundles of muscle fibers and a layer of the circular muscle fibers which surround these bundles. At the ventral side of the sac next is the connective tissue and the skin. At the dorsal side there is connective tissue and external to this are a very thick layer of longitudinal bundles of muscle fibers and a layer of the circular muscle fibers. The mesothelium is continuous with these tissues (Fig. 27G, Fig. 28B).

Fig. 27—II. Clasper and siphon sac in *Mustelus manazo* and *M. griseus*.

- E. Clasper and pelvic fin skeleton of a mature *M. griseus*.
- F. Clasper and pelvic fin skeleton of an immature *M. manazo*.
- G. Transverse section of the siphon sac. *M. griseus*, × 10.
- H. Internal epithelium of the siphon sac. *M. griseus*, × 200.

cm: circular muscle fibers, ct: connective tissue, ep: epithelium, gc: goblet cell, lmf: longitudinal bundles of muscle fibers, ss: siphon sac.



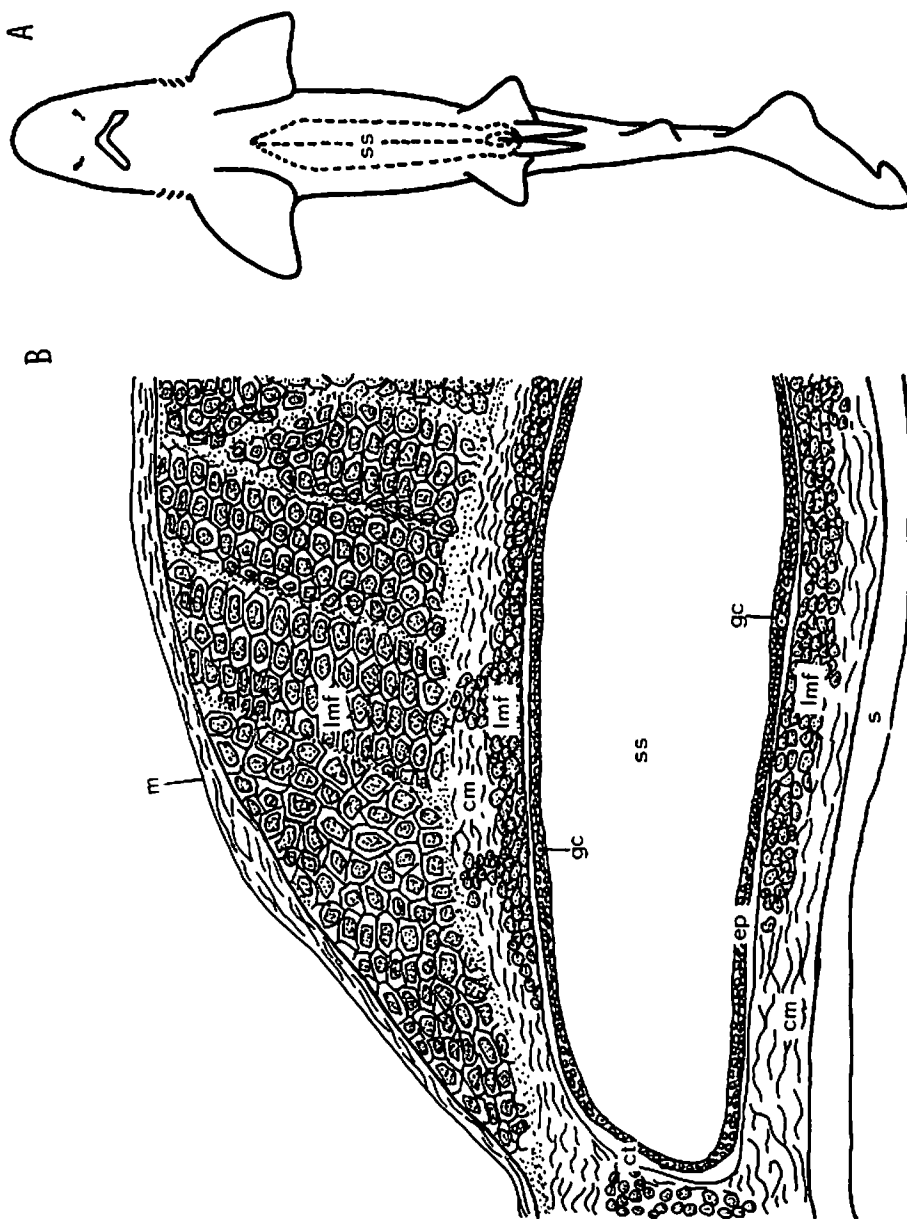


Fig. 28. Siphon sac in *Mustelus manazo* and *M. griseus*.
 A. Representing the situation of the siphon sac.
 B. Simplified drawing of histology of the siphon sac.
 cm: circular muscle fibers, ct: connective tissue, ep: epithelium, gc: goblet cell, lmf: longitudinal bundles of muscle fibers, m: mesothelium s: skin, ss: siphon sac.

Consideration

The siphon sac in the *Mustelus* species is relatively large, and the anterior end of the sac reaches the pectoral region in *M. vulgaris*⁷¹⁾ and *M. lunulatus*⁷²⁾ and *M. canis*⁷⁰⁾ as well as in *M. manazo* and *M. griseus*.

It has been reported that epithelium lining the internal surface of the sac consists of stratified polygonal or cuboidal cells in *Galeus vulgaris*⁷¹⁾, *Cetorhinus maximus*⁷⁾, *Squalus acanthias*⁷⁰⁾ and *Mustelus canis*⁷⁰⁾. Goblet-like cells are also scattered in the epithelium in *C. maximus*, *S. acanthias* and *M. canis*. According to GILBERT and HEATH⁷⁰⁾, goblet cells are very scattered in *M. canis* compared to *S. acanthias*. These goblet cells are found in *M. manazo* and *M. griseus*, but the number is very small. This distribution of goblet cells is similar to that in *M. canis*. Although LEIGH-SHARPE⁷¹⁾ observed large mucus-secreting cells in the epithelium of *G. vulgaris*, he described that these cells are characteristics to this species and do not resemble ordinary goblet cells, such as appear in *Rhina*.

LEIGH-SHARPE⁷³⁾ stated that the siphon sac normally contains sea water and that during copulation, muscular contraction of the siphon wall occurs and the spermatozoa are ejected into the oviduct of the female by the flush of sea water. MATTHEWS⁷⁾, in discussing the function and mode of action of the siphons, however, points out that if the water acts as a propellant to convey the spermatozoa into the oviduct, the spermatozoa would be diluted with the water. He described that no such dilution occurs in the female of *Cetorhinus* which had recently been inseminated, and that it is difficult to understand how the siphons could be filled with sea water. GILBERT and HEATH⁷⁰⁾ actually observed mature male *Squalus acanthias* pumping water into the siphon

sac. They said that it is possible for a shark to fill its two siphons with sea water either by repeatedly flexing both its claspers thus pumping sea water into the siphons, or by swimming through the water with first one clasper and then the other flexed medially, thus directing water upward into the clasper groove and into siphon. They also pointed out that the siphons are not normally filled with sea water.

In *Mustelus manazo* and *M. griseus* function of the siphon sac is still not known.

Usually the male shark possesses the siphon sac. The sac, however, does not exist in *Hexanchus griseus*⁷⁴⁾, *Nolorhynchus platycephalus*⁷⁵⁾ and *Chlamydoselachus anguineus*^{69,72,76)}. Instead of the siphon sac *C. anguineus* has a large cavity at the inner ventral aspect of the proximal end of the clasper^{69,72,76)} LEIGH-SHARPE⁷²⁾ described that this cavity can be used for pumping spermatozoa and is analogous with a siphon. According to LEIGH-SHARPE⁷⁴⁾, *H. griseus*, near the entrance of the apople, also possesses a shallow cavity which appears to be homologous to neither a siphon, nor with the cavity. This shallow cavity has the same function as the siphon sac.

3.5. Maturity

There are some methods to estimate the length at maturity in male sharks. In the present investigation, the length at maturity in male *Mustelus manazo* and *M. griseus* is estimated from the relationship between clasper length and total length, and that between testis weight and total length.

3.5.1. Relationship between the clasper length and total length

In both *Mustelus manazo* and *M. griseus*

the clasper length increases as the shark grows (Fig. 29). The growth curve reveals a slow increase in the clasper length before the shark reaches the total length of 550mm in *M. manazo* and 650mm in *M. griseus*. This is followed by a period of very rapid growth in the clasper length when the total length increases from 550 to 600mm in

M. manazo and 650 to 700mm in *M. griseus*. Following this rapid growth period the clasper still continues to grow but at a slow rate. During the period of rapid growth, the clasper increases its length at the rate of about 0.7cm in both *M. manazo* and *M. griseus* per 1cm increase in the total length.

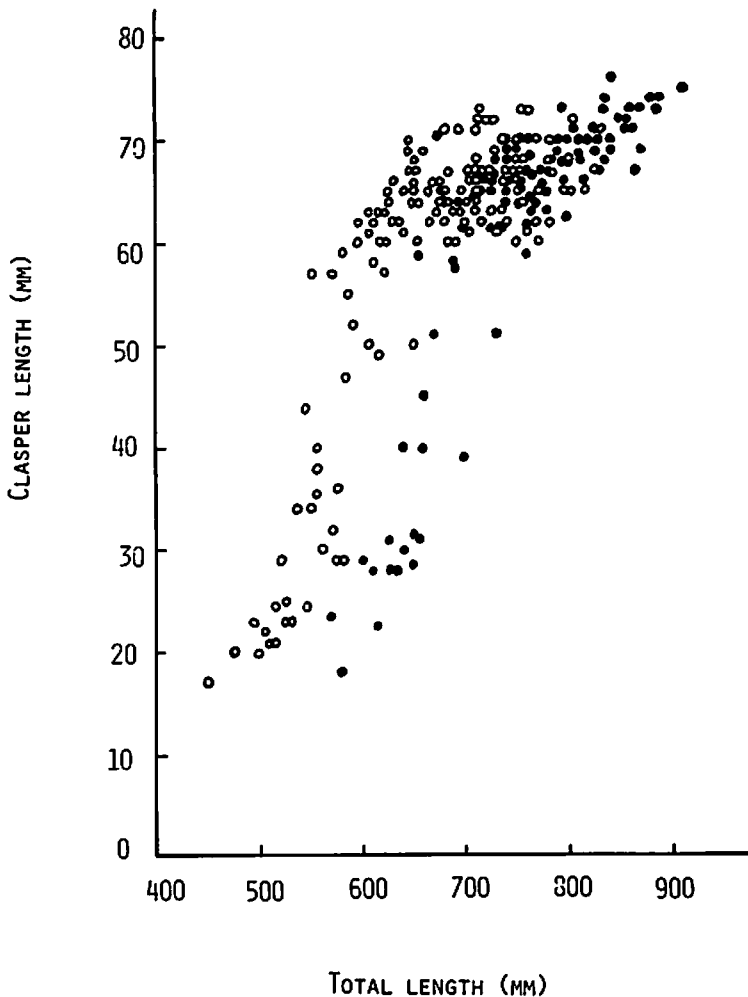


Fig. 29. Relationship between clasper length and total length in *Mustelus manazo* (open circle) and *M. griseus* (closed circle).

3.5.2. Relationship between the testis weight and total length

The testis weight increases as the total length of the shark increases in both *Mustelus manazo* and *M. griseus* (Fig. 30). The testis weight increases slowly before the shark reaches the total length of 650mm in *M. manazo* and 750mm in *M. griseus*. A great rapid increase in the testis weight occurs when the total length increases to more than 650mm in *M. manazo* and 750mm in *M. griseus*.

3.5.3. Consideration

YAMAMOTO and KIBESAKI¹⁹⁾, working with *Squalus suckleyi*, KIBESAKI⁴⁾, with *S. brevirostris*, and CHEN and MIZUE²¹⁾, with *Galeorhinus japonicus*, estimated the length at maturity of male using the relationship between the clasper length and the total length, and that between the testis weight and the total length. TESHIMA et al.²⁴⁾ estimated the length at maturity of male *Mustelus manazo* by the relationship between the clasper length

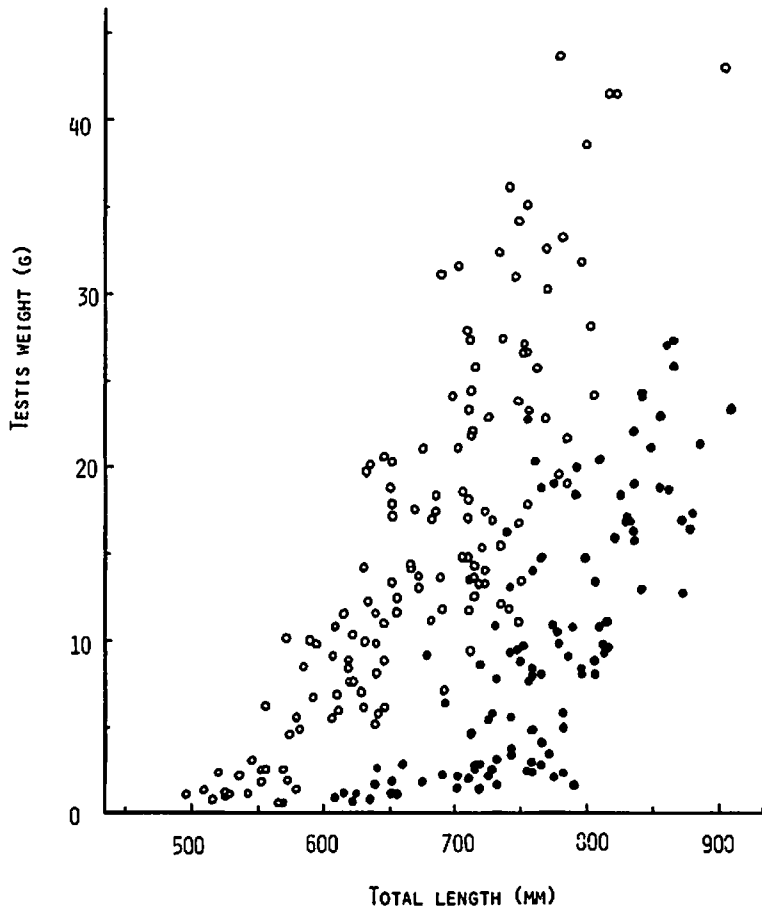


Fig. 30. Relationship between testis weight and total length in *Mustelus manazo* (open circle) and *M. griseus* (closed circle).

and the total length. According to these reports, the clasper length increases rapidly as the shark reaches maturity, but it grows at a much slower rate after reaching maturity. The testis weight also increases as the shark reaches maturity. It is thus estimated that the male *M. manazo* reaches maturity when the shark is between 600 and 650mm in total length, and male *M. griseus* reaches maturity at the total length between 700 and 750mm.

Both *Mustelus manazo* and *M. griseus* reach maturity when the clasper lengths are between 60 and 65mm. Male *M. manazo* reaches maturity when the testis weight is between 7 and 12g, and male *M. griseus* becomes maturity when it is 3 to 8g. Although male *M. manazo* is smaller than *M. griseus* in their length at maturity, the testis of *M. manazo* is much heavier and larger than that of *M. griseus*. Male *M. griseus* is about 100mm longer than male *M. manazo* in their length at maturity.

TESHIMA et al.²⁴⁾, working with *Mustelus manazo* in northern waters of the East China Sea, described that this species reach maturity when it is approximately 600mm in total length.

TANAKA and MIZUE⁵²⁾, working with *Mustelus manazo* occurring in the northern East China Sea, has estimated age of this species using rings formed in the vertebra. According to the growth curve (relationship between age and total length) made by them, the male *M. manazo* of the present investigation is estimated to reach maturity when it is almost two to three years old. Male *M. manazo* seems to reach maturity two to three months earlier than female *M. manazo*.

In Fig. 30 the testis weight of mature individuals of both *Mustelus manazo* and *M. griseus* indicates a striking variability compared with that of the immature individuals. This variation is due to the

fact that the testis weight in mature specimens varies according to the season.

It is not easy to estimate the length at maturity from histological observation of the testis, because spermatogenesis is already occurring in the immature testis. It is also difficult to distinguish between the immature and the mature specimens by the gonad index. The value of the gonad index in June and July is much smaller than that in other months so that the value of the gonad index of the mature shark in June and July corresponds to that of the shark which is in the process of reaching maturity.

4. Taxonomy of Japanese *Mustelus* species

During investigations on the reproduction of the Japanese *Mustelus*, it was noticed that the white spots scattered over the body of *M. manazo* varied from individual to individual. *M. manazo* usually has distinct white spots (Fig. 1A, B), but specimens with indistinct white spots were sometimes found (Fig. 1C, D). Moreover, some individuals with none at all have been observed⁷⁷⁾

According to MATSUBARA^{78,79)}, three species of *Mustelus* occur in the coastal waters of Japan; *M. manazo* BLEEKER⁸⁰⁾, *M. griseus* PIETSCHMANN⁸¹⁾ and *M. kanekonis* (TANAKA)⁸²⁾. In his description, MATSUBARA stated that the only distinct character separating *M. manazo* from other *Mustelus* species is the white spots scattered over its body; other characteristics such as the position of the pectoral fin and first dorsal fin seem to be indistinguishable. Under this classification thus *M. manazo* without white spots is the same as *M. kanekonis*. MATSUBARA's description appears inadequate to classify species of this genus; moreover, it is difficult to separate *M. manazo* without white spots from *M. kanekonis*.

4.1. Japanese species of the genus *Mustelus*

One of the most decisive external characters for separating *Mustelus manazo* from *M. griseus* is the relative lengths of the upper and lower labial folds. In *M. manazo*, the upper fold is markedly longer than the lower while in *M. griseus*, the lower fold is usually slightly longer

than the upper (Fig. 31). NAKAMURA⁸³⁾ described two species of *Mustelus* (*Galeorhinus*) in his investigation on Taiwan sharks; *M. (G.) manazo* (BLEEKER) and *M. (G.) kanekonis* (TANAKA). To distinguish these two species, he refers to the shape of the lower jaw, labial folds, position of the first dorsal fin, and the presence or absence of white spots. NAKAMURA also reported that, in *M. manazo*

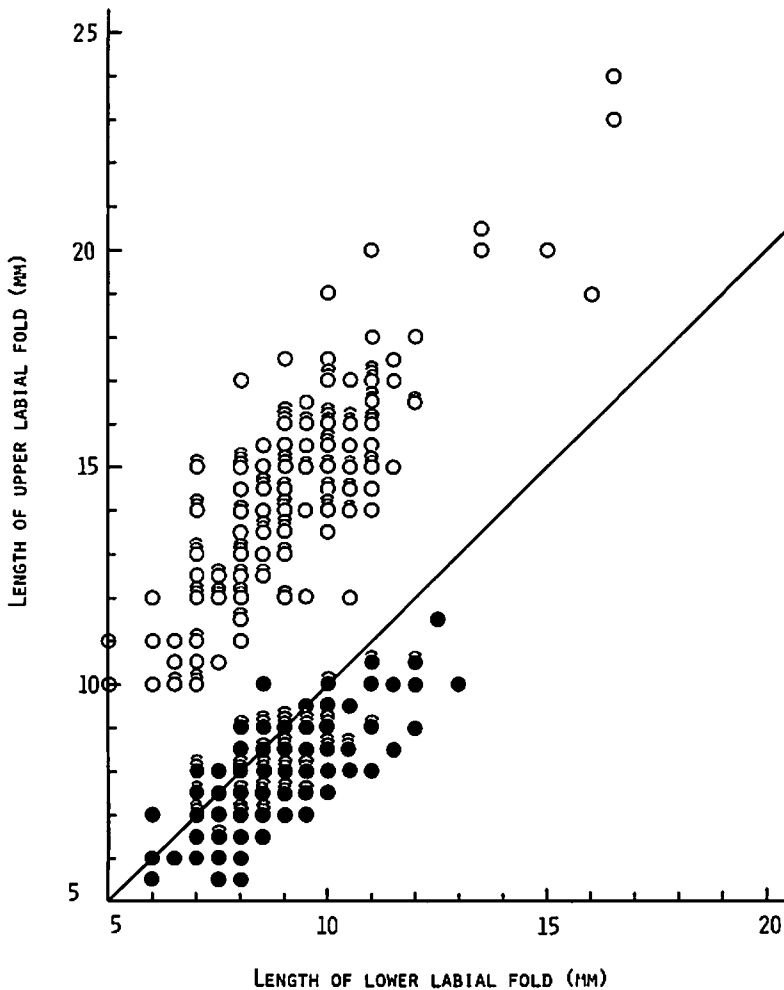


Fig. 31. Relationship between the upper and lower labial fold lengths in *Mustelus manazo* (open circle) and *M. griseus* (closed circle). Straight line: $Y = X$.

the upper labial folds is longer than the lower, and in *M. kanekonis* both labial folds are of almost the same length. It may be therefore considered that *M. griseus* and *M. kanekonis* have the same characteristics in respect to their relative lengths of the upper and lower labial folds.

SPRINGER and GARRICK⁸⁴⁾, HEEMSTRA⁷⁷⁾ and MAKIHATA⁸⁵⁾ have described the vertebral numbers in *Mustelus* species (Table 4). The total vertebral numbers in *M. kanekonis* (130) reported by SPRINGER and GARRICK⁸⁴⁾ are almost the same as those in *M. griseus* (129) reported by MAKIHATA⁸⁵⁾. *M. griseus* has almost the same numbers in monospondylic centra in reports by Heemstra (29 to 35) and Makihata (32.6).

Regarding the relative lengths of the upper and lower labial folds and the vertebral numbers, both *Mustelus griseus* and *M. kanekonis* show the same characteristics; the lower labial fold is usually slightly longer than the upper or both folds are sometimes of the same length; the total vertebral numbers are 129 and 130.

It is therefore considered that *M. griseus* and *M. kanekonis* are conspecific, i.e., *M. kanekonis* is a synonym of *M. griseus*. HEEMSTRA⁷⁷⁾ has also considered that *M. kanekonis* is probably a synonym of *M. griseus*.

Mustelus kanekonis was first found at Nagasaki fish market, Japan by Mr. KANEKO, who called this specimen "Soboshirozame" in Japanese. TANAKA⁸²⁾ considered this shark to constitute a new species, and gave it the scientific name of *M. kanekonis*. In his description, TANAKA pointed out the absence of white spots, the position of pectoral fin, and the shape of the snout and caudal fin as characteristics for separating *M. kanekonis* from *M. manazo*. TANAKA's specimen recorded as a new species was only 43cm in total length. This specimen seems to be still immature because parturition occurs when the embryos are about 30cm in length in both *Mustelus manazo* and *M. griseus* of the present investigation, and the length at maturity is 60–70cm in *M. manazo* and 68–76cm in *M. griseus*. The external

Table 4. *Mustelus* species. Differences in vertebral numbers

Species	P	C	T	M	Sources
<i>M. manazo</i>	90	52	142		SPRINGER and GARRICK ⁸⁴⁾
<i>M. manazo</i>	90	51	141		SPRINGER and GARRICK ⁸⁴⁾
<i>M. kanekonis</i>	81	49	130		SPRINGER and GARRICK ⁸⁴⁾
<i>M. manazo</i>	90.2	48.9	139.2	37.2	MAKIHATA ⁸⁵⁾
<i>M. griseus</i>	81.4	47.6	129.0	32.6	MAKIHATA ⁸⁵⁾
<i>M. manazo</i>				35–40	HEEMSTRA ⁷⁷⁾
<i>M. griseus</i>				29–35	HEEMSTRA ⁷⁷⁾

P: precaudal vertebrae, C: caudal vertebrae, T: total vertebrae, M: monospondylic centra.

The value by MAKIHATA are the average of 78 specimens of *M. manazo* and 60 of *M. griseus*.

characters of the immature individual change as the shark grows. It may be therefore considered that Tanaka regarded an immature *Mustelus* species as a new species.

Mustelus manazo is variously described as follows; as having white spots in TANAKA⁸⁶⁾, MATSUBARA^{78,79)} and NAKAMURA⁸³⁾; as being uniformly grey or with small whitish spots in GÜNTHER⁴⁴⁾; as sometimes with white spots in SMITH⁸⁷⁾; as usually with white spots in CHEN⁸⁸⁾. In DAY^{89,90)} and BLEGVAD⁴⁵⁾, no reference to white spots is made. Thus, white spots are not a good character for separating *M. manazo* from other *Mustelus* species.

Although the embryos of one adult show the same distribution of white spots, it was sometimes noticed during the present investigation that the white spots on the bodies of embryos varied in two uteri of the same specimens; it is considered that individual variation of white spots is, to some extent, due to the genetical factors.

4.2. Reproductive structures as taxonomic criteris

4.2.1. Female

Members of the genus *Mustelus* can be separated into two types with regard to their mode of reproduction; placental and non-placental.

Non-placental type.....*M. manazo*

Placental type.....*M. griseus*

4.2.2. Male

Male *Mustelus manazo* can be separated from male *M. griseus* by the relative lengths of the inner and the outer terminal cartilages consisting the anterior portion of the clasper

The inner terminal cartilage is as long as the outer
.....*M. manazo*

The inner terminal cartilage is markedly longer than the outer
.....*M. griseus*

4.3. Taxonomy

Genus *Mustelus* LINK, 1790

Key to the species

- a¹ Placenta not established; upper labial fold markedly longer than lower; inner terminal cartilage of clasper as long as outer
..... *M. manazo* BLEEKER, 1857
- a² Placenta established; lower labial fold usually slightly longer than upper; inner terminal cartilage of clasper markedly longer than outer
..... *M. griseus* PIETSCHMANN, 1908

5. General Consideration

Since the external characters of *Mustelus manazo* and *M. griseus* closely resemble each other (Fig. 1A, B, E, F), it is not easy to distinguish between them, especially difficult to separate *M. griseus* from *M. manazo* with indistinct white spots (Fig. 1C, D). Investigation of their reproduction has, however, made clear that there are some important differences between two species (Table 5). These differences in reproduction become very useful characteristics in classifying the Japanese species of *Mustelus*.

The reproduction of sharks has been studied by many scientists up to the present day, and a considerable knowledge has been obtained. Some characteristics of reproduction can be listed as follows (as compared to those of the teleosts):
1) The internal fertilization takes place in all species of sharks.
2) The process of oogenesis is more similar to that of the mammals than to that of the teleosts.

3) In the ovary after ovulation the corpus luteum-like tissues are found in some species, 4) The anterior portion of oviduct does not connect with the ovary, 5) In many species the posterior portion of the oviduct is modified to form an uterus, 6) The placenta is formed in many species, ↗

7) The process of spermiogenesis in the spermatogenesis is quite different from those of the teleosts and mammalians, especially in the morphology of spermatozoon^{91,92}, 8) The male shark has a very long spermiduct and a very expanded seminal vesicle, 9) Therefore, the discharge ↘

Table 5. Reproductive differences between *Mustelus manazo* and *M. griseus*.

	<i>M. manazo</i>	<i>M. griseus</i>
Placenta	not formed	formed
Number of embryos	1 to 8	5 to 16
Total length at maturity	F : 630 – 700 mm M : 600 – 650 mm	F : 680 – 760 mm M : 700 – 750 mm
Clasper	ITC as long as OTC	ITC longer than OTC
F : female, M : male.	ITC : inner terminal cartilage length OTC : outer terminal cartilage length	

↙ of spermatozoa takes place when the value of the gonad index reaches a minimum, 10) The male shark has copulatory organs called claspers, 11) The axial structure of clasper consists of several pieces of cartilages, structure and shape of which are different by species, 12) The urino-genital papilla does not connected with the clasper groove, 13) Most male sharks have the siphon sacs.

The present author has made a trial classification of the selachians by their reproductive mode as shown in Fig. 32. In this classification the term ovoviviparity, which has been used up to the present, is not included. The selachian can be divided into two large groups, oviparity and viviparity, based on morphology of embryos at the stage of deposition. Two types of oviparous species have been reported. 1) An embryo is deposited at early development with the egg capsule, e.g., in *Heterodontus japonicus* an embryo at the blastula stage is deposited enclosed in an egg capsule⁹³. This mode of development is called single oviparity by

NAKAYA⁹⁴. According to him, this also occurs in *Cephaloscyllium*, *Scyliorhinus*, *Apristurus* and Japanese *Galeus* species. 2) A relatively well developed embryo is deposited with the egg capsule, e.g., in *Halaaelurus buergeri* an embryo up to about 70mm in length is deposited with the egg capsule after growing in the uterus for six to eight months⁹⁵. This mode of development is named multiple oviparity by NAKAYA⁹⁴ where several of eggs are contained simultaneously in each uterus. This mode also occurs in *H. boesemani*⁹⁶, *H. lineatus*⁹⁶ and *H. natalensis*⁹⁶. In viviparous species a full grown embryo, similar in shape to adult, is born alive. Two types are known to exist ;1) the non-placental and 2) the placental species. 1) In the non-placental species, a placenta is not formed during the whole stage of gestation. In most non-placental sharks the uterine compartments develop during gestation, though some species, e.g., *Chlamydoselachus anguineus*⁹⁷ and *Heptranchias perlo*³⁷ do not form the compartments. 2) In the placental type, the placenta is established

and the embryo is nourished by the mother. In most placental sharks the placenta is established at the middle stage of gestation, e.g., in *Sphyrna tiburo* the placentation commences at about three and a half months after fertilization³⁶⁾. It has been, however, reported that a few species, e.g., *Scoliodon sorrakowah*^{1,2)} and *S. laticaudus*⁴⁷⁾, establish the placenta immediately after implantation. Gravid females usually contain more than two embryos in each uterus simultaneously and this mode is called multiple pregnancy²⁰⁾. *Carcharhinus dussumieri* occurring in the South China Sea has, however, only one embryo in each uterus during gestation and this is called simple pregnancy²⁰⁾.

In viviparous sharks embryos grow in the uterus until parturition. There are,

however, some variations in the mode of reproduction by various groups of sharks as has been indicated in the reproductive classification. The present author has suggested a tentative evolutionary development of viviparous sharks based on their mode of reproduction (Fig. 33). This classification includes four modes of reproduction from the most primitive (mode I) to the most advanced (Mode IV).

In mode I, an embryo enclosed in an egg capsule is hatched in the uterus where it grows until parturition. In *Chlamydoselachus anguineus* an embryo, which has grown in the egg capsule, is hatched in the uterus at the length of about 170mm. After this stage the embryo continues to grow in the uterus until parturition⁹⁷⁾. This mode of

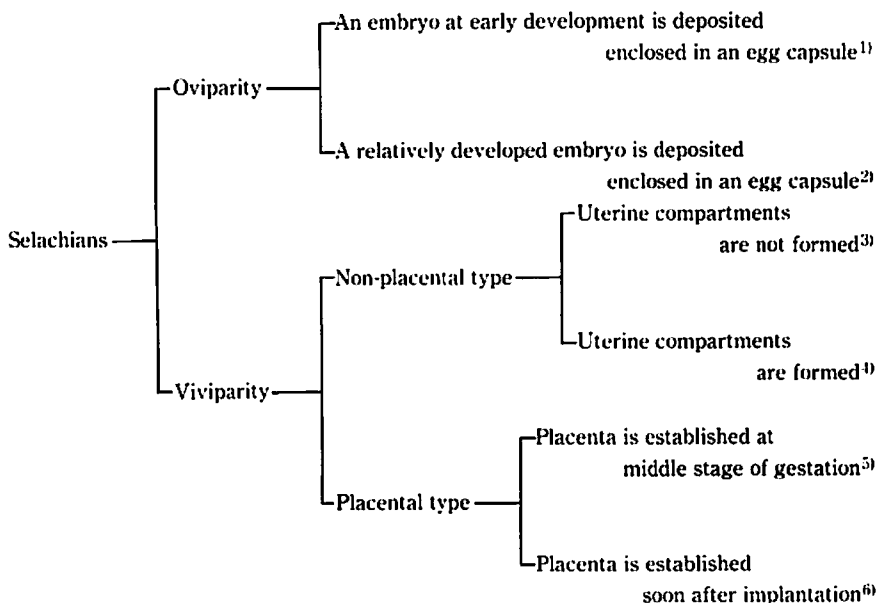


Fig. 32. Reproductive classification in selachians

Representative species

- | | |
|---|---|
| 1) <i>Heterodontus japonicus</i> (DUMÉRII). | 4) <i>Mustelus manazo</i> BLEEKER |
| 2) <i>Halaclurus buergeri</i> (MÜLLER et HENLE) | 5) <i>Mustelus griseus</i> PIETSCHMANN |
| 3) <i>Chlamydoselachus anguineus</i> GARMAN | 6) <i>Scoliodon sorrakowah</i> (CUVIER) |

reproduction is therefore considered to be an advanced form of the oviparous *Halaehurus buergeri* where an embryo up to about 70mm in length is deposited with the egg capsule. Thus, Mode I may be the first status of viviparity evolved from oviparity. *Hepranchias pelro*³⁷⁾ also belongs to Mode I. *Ginglymostoma cirratum*⁴²⁾ of family Orectolobidae and *Galeus polli*⁹⁸⁾ of family Scyliorhinidae seem to be involved in Mode I. In Mode II, the uterine compartments are formed and an embryo, enclosed in an embryonic membrane, grows in one compartment until parturition. This mode is reported in sharks of suborder Squalina and genus *Galeorhinus* by MATSUBARA⁷⁹⁾, and is also known to occur in *Mustelus manazo* of the genus *Mustelus*. The embryonic membrane is considered to be an advanced form of the egg capsule. In viviparous species since the embryo grows in the uterus, such a thick egg capsule found in the oviparous species is unnecessary to protect the embryo. It is thus considered that the egg capsule has been transformed into a thin, transparent membrane which occurs in Mode II and Mode III. From this point of view Mode I may be transitional stage from an egg capsule to an embryonic membrane. In sharks of both Mode I and Mode II, embryos are nourished mainly by yolk. In *M. manazo*, yolk mass is still contained within the intestine of the embryo even after parturition. In Mode III, the placenta is established at the middle stage of gestation. This mode of reproduction is found in sharks of families Sphyrinidae and Carcharhinidae, and is also found in some members of the genus *Mustelus*, including *M. griseus*. In *M. griseus* even a full termed embryo still contains yolk mass within the intestine. It may be said therefore that the embryo is nourished by both yolk and placenta after establishment of the placenta. It is

common to the placenta of Mode III that an embryonic membrane intervenes between the foetal and maternal placentae and the epithelium of the foetal placenta is greatly reduced in thickness^{32,33,35,36,46)}. *Carcharhinus dussumieri* belongs to Mode III, but simple pregnancy occurs in the species unlike other sharks in Mode III. *C. dussumieri* is therefore considered to be a little more advanced form of Mode III. In Mode IV, placentation commences soon after implantation. The yolk is not contained within the yolk sac even in the earliest stage of gestation. The embryo is thus nourished by the mother from the earliest stage of gestation. As far as has been investigated, this mode occurs in *Scoliodon sorrakowah*^{1,2)} and *S. laticaudus*⁴⁷⁾. Unlike sharks of Mode III, the embryonic membrane does not exist in the placenta of these two species. The foetal placental portion is directly in touch with the maternal placental portion. It may be therefore said that the structure of the foetal-maternal junction of the placenta in both *S. sorrakowah* and *S. laticaudus* is similar to that in mammalians. This mode of reproduction may be the most advanced in the selachians. AMOROSA⁹⁹⁾ also indicated that in the ripe placenta of *S. sorrakowah* the connection between mother and offspring becomes purely vascular as in mammalians.

With the exception of Mode IV, embryos in other Mode (I to III) are nourished by yolk. In sharks of Mode I and Mode II embryos clearly depend on yolk. Even in sharks of Mode III the yolk which is absorbed from the yolk sac is still present in the intestine of the embryo after establishment of the placenta. In Mode III, the embryo is first nourished by yolk and later by both yolk and mother after establishment of the placenta. The embryonic development in Mode III may be expressed as follows if the term

ovoviviparity is used here : the early developmental stage is ovoviviparous, and the late development after the establishment of the placenta is both ovoviviparous and viviparous. It may be

thus stated the placental species, if the species depends on the yolk in the embryonic development, is not truly viviparous. Reproductive classification based on morphology at the deposition of

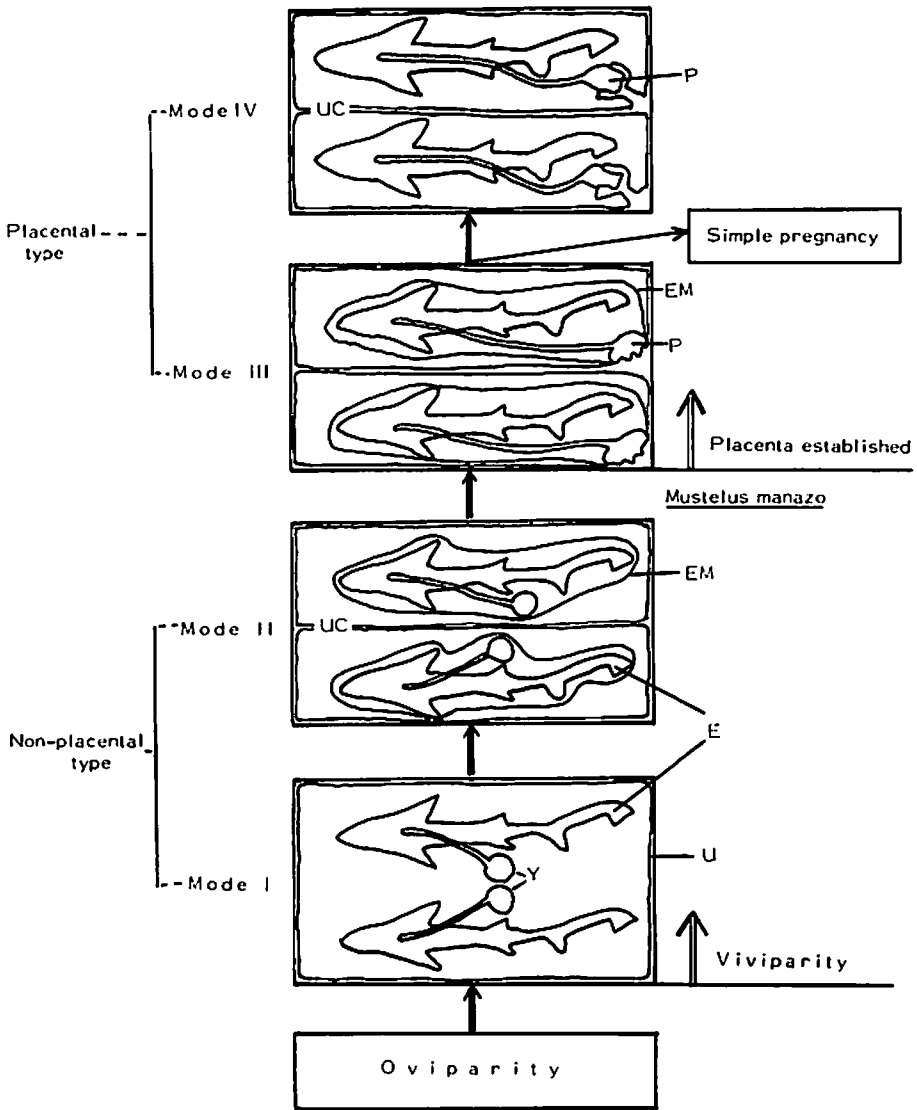


Fig. 33. The tentative evolutionary development of viviparous sharks based on reproductive characteristics. E: embryo, EM; embryonic membrane, P: placenta, U: uterus, UC: uterine compartment, Y: yolk sac.

the embryo may be easily understood as has been indicated by the present author. The term ovoviviparity is not therefore included in the present study.

As has been described above histological variations occur in the foetal-maternal junction of the placenta, and placentae found in all living sharks can be divided into five types (from A to E) based on their mode of the junction: A) The embryonic membrane intervenes between the greatly reduced foetal placental epithelium and the maternal placental epithelium consisting of a single layer of columnar cells. This type of placenta occurs in *Carcharhinus dussumieri*¹⁾ and *C. falciformis*³⁵⁾ where the foetal placenta just rests on the maternal placenta. B) The greatly reduced epithelia of the foetal and maternal placentae are in contact with the embryonic membrane. This type occurs in *Sphyrna tiburo*.³⁶⁾ C) The foetal capillary network and greatly reduced epithelium of the maternal placenta are in touch with the embryonic membrane. *Mustelus laevis*³²⁾ belongs to this type. D) Both foetal and maternal capillaries are bounded by the embryonic membrane. This type of the placenta is seen in *M. griseus*. E) The reduced foetal epithelium of the placenta is directly in contact with the epithelium of the maternal placenta. This type of placenta occurs in *Scoliodon sorrakowah*^{1,2)} and *S. laticaudus*³⁷⁾. Among the five types of placentae an interdigitation between the foetal and maternal placental portions occurs in Type B, Type C and Type D. The union between the foetal and maternal tissues in these three types of placentae is therefore much more tight than that in the Type A where a foetal placenta just rests on a maternal placental area. The placenta in Type E differs from others in having a special structure called trophonematous cup formed by a modification of

the maternal placenta and this cup contains the foetal placental portion. In sharks with Type E of placenta embryos are nourished by the placenta throughout the entire stage of gestation. The connection between the foetal and maternal placentae suggests that Type A of placenta is the most primitive one while Type E is the most advanced one, i.e., the mode of placentation progresses from Type A to Type E. Placentae from Type A to Type D occur in sharks of Mode III defined above. Since the placenta in *Mustelus* species is involved in Type C and Type D, the placental *Mustelus* species seem to be a little more advanced in mode of placentation than other species of Mode III.

Nineteen families of sharks occur in the waters around Japan as listed in Table 6. Fifteen of them are probably viviparous. Three of them, the family Triakidae, the family Carcharhinidae and the family Sphyrnidae are placental viviparous. Sharks of the family Triakidae are sometimes included in the family Carcharhinidae¹⁰⁰⁾, but here they are separated from the family Carcharhinidae based on MATSUBARA⁷⁹⁾. Oviparity occurs in four families, but two families of these, the family Scyliorhinidae and the family Orectolobidae, include viviparous species. One species known as viviparity in the family Scyliorhinidae is *Galeus polli* which gives birth to living, fully grown embryo of about 115mm in length¹⁰⁰⁾. An egg capsule enclosing an embryo appears to be absorbed in early stage of embryonic development in the uterus¹⁰⁰⁾. Other species in the genera of the family Scyliorhinidae are oviparous¹⁰⁰⁾. The family Orectolobidae has some viviparous species, e.g., *Ginglymostoma cirratum* and *Orectolobus japonicus*. In *G. cirratum*¹²⁾, an embryo, which has been enclosed in an egg capsule in early developmental stage, is born alive. Such species as *G. polli*, *G. cirratum* and

O. japonicus discussed here belong to Mode I defined above. Species in two families, Scyliorhinidae and Orectolobidae, are thus considered to be transitional type from oviparity to viviparity. WOURMS¹⁰¹⁾, working with reproduction and development in chondrichthyan fishes, has pointed out eight factors such as phylogenic position, geographical distribution and others in connection with the discussion of evolution of viviparity. He stated that eight factors are considered to affect the retention of oviparity or the evolution of

viviparity, and also that viviparity seems to have evolved independently. It is, however, considered that oviparity and viviparity cannot be positioned independently, but oviparity is continuous with viviparity on a line of evolutionary development based on the mode of reproduction, i.e., oviparous species involves a possibility of developing into viviparity as found in species of the families Scyliorhinidae and Orectolobidae.

The size of the ovarian egg tends to become smaller as the mode of repro-

Table 6. Modes of reproduction in sharks

Modes of reproduction	Sharks
Oviparity	Family Heterodontidae
	Family Rhincodontidae
	Family Scyliorhinidae
	Family Orectolobidae
Viviparity	Family Scyliorhinidae
	Family Orectolobidae
	Family Chlamydoselachidae
	Family Hexanchidae
	Family Odontaspidae
	Family Scapanorhynchidae
	Family Lamnidae
	Family Cetorhinidae
	Family Alopiidae
	Family Squalidae
	Family Dalatiidae
	Family Echinorhinidae
	Family Pristiophoridae
	Family Squatinidae
Family Triakidae*	
Family Carcharhinidae*	
Family Sphyrnidae*	

(Based on Matsubara⁷⁹⁾)

*Three families include placental viviparous species.

duction evolves, e.g., the mature oocyte reaches the diameter of about 80mm in *Chlamydoselachus anguineus*⁹⁷⁾ of Mode I, about 40mm in *Galeorhinus japonicus*²¹⁾ of Mode II, about 15mm in *Mustelus griseus*²²⁾ of Mode III and only about 1mm in *Scoliodon laticaudus*⁴⁷⁾ of Mode IV. The size of the ovarian egg may be therefore a reliable characteristic in determining evolutionary trends of viviparity in selachians.

An internal yolk sac is not formed in the embryo of the placental *Mustelus griseus* throughout the whole stage of embryonic development. The internal yolk sac of the embryo in *M. manazo* is much smaller in size than those in other species, e.g., *Squalus acanthias*³⁸⁾ and *Etmopterus lucifer*³⁹⁾. The internal yolk sac in *M. manazo* reaches a maximum in diameter (4–5mm) and length (13–15mm) when the embryo is about 210–220mm in total length while in *E. lucifer*³⁹⁾ it is about 10mm in diameter and about 40mm in length when the embryo is about 130mm in length. Since the embryo at birth is about 300mm in total length in *M. manazo* and it is about 150mm in total length in *E. lucifer*, the internal yolk sac in *M. manazo* is much smaller even though the *M. manazo* embryo is nearly twice as large in length as the *E. lucifer* embryo. The internal yolk sac in *M. manazo* disappears before parturition occurs. From these facts the internal yolk sac in *M. manazo* seems to have been degenerating and then it may become rudimentary. As has been described above the internal yolk sac is not formed in the embryos of sharks of Mode III, and moreover in Mode IV, even yolk does not exist in the yolk sac of the embryo. It may be therefore said that the size of the internal yolk sac tends to become smaller and then it disappears as the mode of reproduction in viviparity evolves.

With regard to genus *Mustelus*, it is not easy to understand why two modes of reproduction, non-placental and placental types occur in a genus. Among the members of genus *Mustelus* occurring in the western Atlantic Ocean, species which have a relationship similar to that between *M. manazo* and *M. griseus* are found. These are *M. asterias*, *M. mustelus* and *M. canis*. Of these, both *M. mustelus* and *M. canis* develop the placenta during gestation while *M. asterias* does not^{33,42,44)}.

In addition to this, although these three species closely resemble one another in general appearance, *M. asterias* is distinguishable from *M. mustelus* and *M. canis* in having white spots scattered over the body⁴²⁾. The facts described above suggest that the three Atlantic species of *Mustelus* resemble the Japanese species of *Mustelus* in the taxonomical aspect as well as the mode of reproduction. It is of interest to note that two groups of *Mustelus* species, similar in the relationship between the taxonomical and reproductive aspects, are now occurring respectively in the two different areas, and that a geographical distance does exist between the two areas. Regarding Japanese *Mustelus*, both *M. manazo* and *M. griseus* are benthic and feed on crustaceans and mollusks. They are caught together by bottom long liners and trawlers. As far as has been concerned with the Japanese *Mustelus*, both *M. manazo* and *M. griseus* closely resemble each other in both morphological and ecological aspects. It may not be therefore considered that different modes of reproduction in the genus *Mustelus* were caused by differences in the environmental condition as was suggested by TORTONESE¹⁰²⁾ and WOURMS¹⁰¹⁾. TORTONESE¹⁰²⁾ paid attention to a relationship between habitat and the mode of reproduction. He mentioned that oviparous species are benthic, chiefly littoral and

not of a large size ; those viviparous vary both morphologically and ecologically. Through the description made above, a following thing is tentatively considered as to the different modes of reproduction found in the Japanese *Mustelus* species : Two species with different modes of reproduction first occurred in the different areas, and then they happened to live together in the same area. This may be suggested by a fact that *M. manazo* is not positioned near *M. griseus* from the viewpoint of evolutionary development because *M. griseus* has a relatively advanced placenta compared with those of other species.

Summary

Since *Mustelus manazo* and *M. griseus* closely resemble each other in general appearance, these smooth dogfishes were consistently confused by previous workers in classification. The detailed studies on the reproductive organs and reproductive patterns in these two species revealed some remarkable differences between them. Especially, reproductive patterns are distinctly different, i.e., *M. griseus* is placental viviparous species, though *M. manazo* is non-placental species. General reproductive characters of these two species are summarized as follows :

Female :

1. The female reproductive organs in both species consist of the ovary, oviduct, nidamental gland and uterus. Eggs ovulated from the ovary are received through the common ostium and distributed to both oviducts. Fertilization takes place in the nidamental gland, and a fertilized egg enclosed in an embryonic membrane descends into the uterus to develop into an

embryo. The size of the egg at ovulation is about 20mm in diameter in *M. manazo* and about 15mm in *M. griseus*.

2. In both species ovulation and fertilization occur during the period from July to August, and embryos of about 300mm in total length are born during the next April and May. Gestation period in both species is therefore estimated to be about ten months.
3. In *M. griseus* the placenta is established when the embryo is about 150mm in total length, and the embryo is nourished by both yolk and mother after establishment of the placenta. In *M. manazo* the placenta is not formed throughout the whole stage of gestation. The *M. manazo* embryo therefore seems to be nourished by yolk until parturition. The internal yolk sac is formed in the *M. manazo* embryo while it is not formed in the *M. griseus* embryo.
4. In both species an embryo enclosed in an embryonic membrane is contained in each uterine compartment. The number of embryos per litter increases with adult length in both species.
5. Female *M. manazo* is estimated to reach maturity at the total length between 630 and 700mm, and the size at maturity in female *M. griseus* is estimated to be between 680 and 760mm in total length.

Male :

1. The male reproductive organs in both species consist of the testis, epididymis, spermiduct, seminal vesicle, siphon sac and claspers. Spermatozoa, produced in the testis, are accumulated in the seminal

vesicle after passing through the epididymis and spermiduct. During mating spermatozoa are sent into the uterus through the clasper groove.

2. In both species the value of the gonad index reaches the maximum in November and December, and reaches the minimum in June to July, when the spermatozoa discharge (mating) occurs. The mating season agrees with the ovulating season. In both *M. manazo* and *M. griseus*, ovulation, mating and fertilization thus take place during the period from June to August.
3. The clasper is the copulatory organ and is formed by a modification of the pelvic fin. A clear difference is found in the distal portion of the clasper skeleton between the two species; in *M. manazo*, the inner terminal cartilage is as long as the outer terminal cartilage while in *M. griseus*, the inner terminal cartilage is markedly longer than the outer terminal cartilage. The clasper skeleton is formed when the shark is between 620 and 650mm in total length in *M. manazo* and between 720 and 750mm in *M. griseus*.
4. In both species the siphon sac is formed in the ventral region. During mating, spermatozoa, pushed out of the urino-genital papilla, seem to be ejected into the uterus through the clasper groove by the flush of water from the siphon sac.
5. Male *M. manazo* is estimated to reach maturity when the shark is between 600 and 650mm in total length, and male *M. griseus* is estimated to reach maturity at the total length between 700 and 750mm.

References

- 1) MAHADEVAN, G. 1940 Preliminary observation on the structure of uterus and the placenta of a few Indian elasmobranchs. *Proc. Indian Acad. Sci. (Sect. B)*, 11: 2—40.
- 2) SETNA, S.B. and P.N. SARANGDHAR. 1948. Description, bionomics and development of *Scoliodon sorrakowah* (CUVIER). *J. Indian Zool.*, 156; 25—53.
- 3) SETNA, S.B. and P.N. SARANGDHAR. 1949. Studies on the development of some Bombay elasmobranchs. *J. Indian Zool.*, 157: 203—216.
- 4) KIBESAKI, O. 1954. Studies on the sharks from the East China and Yellow Seas. (II). Maturity of the *Squalus brevirostris*. *Bull. Seikai Reg. Fish. Res. Lab.*, 5: 36—46. (In Japanese).
- 5) KUDO, S. 1956. On *Squalus brevirostris* in Hyuga-Nada. *Rep. Nankai Reg. Fish. Res. Lab.*, 3: 66—72. (In Japanese).
- 6) SAMUEL, M. 1943. Studies on the corpus luteum in *Rhinobatus glanulatus* CUV. *Proc. Indian Acad. Sci. (Sect. B)*, 18: 133—156.
- 7) MATTHEWS, L.H. 1950. Reproduction in the basking shark, *Cetorhinus maximus* (GUNNER). *Phil. Trans. Roy. Soc. London. Series B*, 234: 247—316.
- 8) YAMAMOTO, K. 1954. Studies on the maturity of marine fishes. II. Maturity of the female fish in the flounder, *Liopsetta obscura*. *Rep. Hokkaido Reg. Fish. Res. Lab.*, 11: 68—77. (In Japanese).
- 9) MIZUE, K. 1959. Studies on a scorpaenous fish *Sebastiscus marmoratus* CUVIER et VALENCIENNES—V. On the maturation and the seasonal cycle of the ovaries of the marine ovoviviparous teleost. *Bull. Fac. Fish. Nagasaki Univ.*, 8: 83—110. (In Japanese).
- 10) MIZUE, K. 1961. Studies on a marine

- viviparous teleost, *Direma temmincki* BLEEKER—III. About the maturation and the seasonal cycle of the ovary. *Bull. Fac. Fish. Nagasaki Univ.*, 11: 1—18. (In Japanese).
- 11) WALLACE, W. 1903. Observations on ovarian ova and follicles in certain teleostean and elasmobranch fishes. *Quart. J. Mic. Sci. n.s.* 47: 161—213.
 - 12) HISAW, F.L. and A. ALBERT. 1947. Observations on the reproduction of the spiny dogfish, *Squalus acanthias*. *Biol. Bull.* 92: 187—199.
 - 13) HISAW, F. L. Jr. and F. L. HISAW. 1959. Copora lutea of elasmobranch fishes. *Anat. Rec.*, 135: 269—277.
 - 14) TEWINKEL, L.E. 1972. Histological and histochemical studies of post-ovulatory and pre-ovulatory atretic follicles in *Mustelus canis*. *J. Morph.*, 136: 443—457.
 - 15) YOSHIDA, K., N.BABA, M. OYA and K. MIZUE. 1977. On the formation and regression of corpus luteum in the northern fur seal ovaries. *Sci. Rep. Whales Res. Inst.*, 29: 121—128.
 - 16) YOSHIDA, K., N.BABA, M. OYA and K. MIZUE. 1978. Seasonal changes in the ovary of the northern fur seal. *Bull. Far. Seas. Fish. Res. Lab.*, 16: 93—101.
 - 17) TESHIMA, K., C.T.CHEN and K.MIZUE. 1976. Studies on sharks—IX. Ovary and oogenesis in selachians. *J. Shimonoseki Univ. Fish.*, 25: 41—45.
 - 18) LANCE, V. and I.P. CALLARD. 1969. A histochemical study of ovarian function in ovoviviparous elasmobranch, *Squalus acanthias*. *Gen. Compar. Endocrinol.*, 13: 255—267.
 - 19) YAMAMOTO, T and O. KIBESAKI. 1949. Studies on the spiny dogfish *Squalus suckleyi*. On the development and maturity of the genital glands with growth. *Bull. Jap. Soc. Scient. Fish.*, 15: 531—538. (In Japanese).
 - 20) TESHIMA, K. and K. MIZUE. 1972. Studies on sharks. I. Reproduction in the female sumitsuki shark *Carcharhinus dussumieri*. *Mar. Biol.*, 14: 222—231.
 - 21) CHEN, C.T. and K.MIZUE. 1973. Studies on sharks—VI. Reproduction of *Galeorhinus japonicus*. *Bull. Fac. Fish. Nagasaki Univ.*, 36: 37—51.
 - 22) TESHIMA, K., K. MIZUE and S. KOGA. 1974. Studies on sharks—VII. Reproduction in female *Mustelus griseus*. *J. Shimonoseki Univ. Fish.*, 22: 199—206.
 - 23) KUDO, S. 1958. Studies on the sexual maturation of female and embryos of Japanese dogfish *Mustelus manazo*. *Rep. Nankai Reg. Fish. Res. Lab.*, 9: 60—62. (In Japanese).
 - 24) TESHIMA, K., H. YOSHIMURA and K. MIZUE. 1971. Studies on sharks—II. On the Reproduction of Japanese dogfish *Mustelus manazo* BLEEKER. *Bull. Fac. Fish. Nagasaki Univ.*, 32: 41—50.
 - 25) HISAW, F.L. and A.A. ABRAMOWITZ. 1938. The physiology of reproduction in the dogfish, *Mustelus canis*. *Report Woods Hole Oceanogr. Inst.* 1937: 21—22.
 - 26) HISAW, F.L. and A.A. ABRAMOWITZ. 1939. Physiology of reproduction in the dogfish, *Mustelus canis* and *Squalus acanthias*. *Report Woods Hole Oceanogr. Inst.* 1938: 22
 - 27) METTEN, H. 1939. Studies on the reproduction of the dogfish. *Phil. Trans. Roy. Soc. London. Series B*, 230: 217—238.
 - 28) TEWINKEL, L.E. 1956. Spermatozoa in the oviducal gland of the smooth dogfish, *Mustelus canis*. *Biol. Bull.*, 102: 314.
 - 29) TEWINKEL, L.E. 1950. Notes on ovulation, ova and early development in the smooth dogfish, *Mustelus canis*.

- Biol. Bull.*, 99 : 474—486.
- 30) WIDAKOWICH, V. 1907. Über den Uterus von *Squalus acanthias*. *Z. Wiss. Zool.*, 88 : 499—544.
- 31) PARKER, J. 1882. On the gravid uterus of *Mustelus antarcticus*. *Trans. Proc. New Zealand Inst.*, 15 : 219—222.
- 32) TEN CATE-HOEDEMARKER, N.J. 1933. Beiträge zur Kenntnis der Plazentation bei Haien und Reptilien. Der Bau der reifen Plazenta von *Mustelus laevis* RISSO und *Seps chalicoides* MERR. (*Chalcides tridactylus* LAUR.). *Zeit. Zellforsch. Mikr. Anat. Bd.*, 18 : 299—345.
- 33) RANZI, S. 1934. Le basi fisiomorfologiche dello sviluppo embrionale dei Selaci—Part II et III. *Pubb. Staz. Zool. Napoli*, 13 : 331—437.
- 34) BÖKER, H. 1938. Bilder zur Plazenta der Blauhais. *Verhandlungen Anat. Gesellschaft jene, Ergänzungsheft Anat. Anzeiger*, 87 : 289—293.
- 35) GILBERT, P.W. and D.A. SCHLERNITZAUER. 1966. The placenta and gravid uterus of *Carcharhinus falciformis*. *Copeia* 1966 : 451—547.
- 36) SCHLERNITZAUER, D.A. and P.W. GILBERT. 1966. Placentation and associated aspects of gestation in the bonnethead shark, *Sphyrna tiburo*. *J. Morph.*, 120 : 219—232.
- 37) TANAKA, S. and K. MIZUE, 1977. Studies on sharks—XI. Reproduction in female *Heptranchias perlo*. *Bull. Fac. Fish. Nagasaki Univ.*, 42 : 1—9.
- 38) TEWINKEL, L.E. 1943. Observations on late phases of embryonic nutrition in *Squalus acanthias*. *J. Morph.*, 73 : 177—205.
- 39) IWAI, T. 1957. The sequence of yolk absorption in the embryo of the deep-sea luminous shark, *Etmopterus lucifer* JORDAN and SNYDER. *Bull. Jap. Soc. Scient. Fish.*, 23 : 295—301.
- 40) WISLOCKI, G.B. and G.L. STREETER. 1938. On the placentation of the macaque (*Macaca mulatta*), from the time of implantation until the formation of the definitive placenta. *Contr. to Embryol.*, 160 : 1—66.
- 41) HEUSER, C.H. and G.L. STREETER. 1941. Development of the macaqua embryo. *Contr. to Embryol.*, 181 : 1—15.
- 42) BIGELOW, H.B. and W.C. SCHROEDER. 1948. Sharks. In Fishes of the western North Atlantic. No. 1. Part 1. *Mem. Sears. Fdn. Mar. Res.*, 59—576.
- 43) CLARK, E. and K. von SCHMIDT. 1965. Sharks of the Central Gulf coast of Florida. *Bull. Mar. Sci.*, 15 : 13—83.
- 44) GÜNTHER, A. 1870. Catalogue of fishes in British Museum. Vol. VIII, 549pp. London.
- 45) BLEGVAD, H. 1940. Fishes of the Iranian Gulf. Danish scientific investigation in Iran. Part III. 247pp. Einar Munksgaard. Copenhagen.
- 46) CALZONI, M. 1936. Ricerche sulla placenta del *Carcharias glaucus*. *Publ. Staz. Zool. Napoli*, 15 : 169—174.
- 47) TESHIMA, K., M. AHMAD and K. MIZUE. 1978. Studies on sharks—XIV. Reproduction in the Telok Anson Shark collected from Perak River, Malaysia. *Japan. J. Ichthyol.* 25 : 181—189.
- 48) ALCOCK, A. 1890. Observations on the gestation of some sharks and rays. *J. Asiat. Soc. Bengal*, 69 : 51—56.
- 49) BUDKER, P. 1953. Sur le cordon ombilical des Squales vivipares. *Bull. Mus. nat. Paris Ser. 2*, 25 : 541—545.
- 50) TESHIMA, K. 1973. Studies on sharks—III. The stage of placentation and the umbilical stalk in *Carcharhinus dussumieri*. *J. Shimonoseki Univ. Fish.*, 21 : 25—30.
- 51) TEWINKEL, L.E. 1963. Notes on the smooth dogfish, *Mustelus canis*, during

- first three months of gestation. II. Structural modification of yolk sacs and yolk stalks correlated with increasing absorptive function. *J. Exp. Zool.*, **152**: 115—122.
- 52) TANAKA, S. and K. MIZUE. 1979. Age and growth of Japanese dogfish, *Mustelus manazo* BLEEKER in the East China Sea. *Bull. Jap. Soc. Sci. Fish.*, **45**: 43—50.
- 53) MIZUE, K. 1958. Studies on a scorpaenous fish *Sebastiscus marmoratus* CUVIER et VALENCIENNES—II. The seasonal cycle of mature testis and the spermatogenesis. *Bull. Fac. Fish. Nagasaki Univ.*, **6**: 27—38. (In Japanese).
- 54) CHEN, C.T., K. TESHIMA and K. MIZUE. 1973. Studies on sharks—IV. Testes and spermatogenesis in selachians. *Bull. Fac. Fish. Nagasaki Univ.*, **35**: 53—65.
- 55) MOORE, J.E.S. 1895. On the structural change in the reproductive cells during the spermatogenesis of elasmobranchs. *Quart. J. Micr. Sci.*, **38**: 275—313.
- 56) TOGARI, C. 1954. Histology (Textbook). 397pp. Nanzan Do. Tokyo. (In Japanese).
- 57) SANDHORN, E.B. 1974. Cells and tissues by light and electron microscopy. 381pp. Trans. by MAKITA, T. Tokyo Daigaku Shuppankai. Tokyo.
- 58) YAMAMOTO, K. 1953. Studies on the maturity of marine fishes. I. Seasonal cycle in the spermary of the flounder, *Liopsetta obscura*. *Rep. Hokkaido Fish. Res. Lab.*, **8**: 52—62. (In Japanese).
- 59) MIZUE, K. 1957. Studies on a scorpaenous fish *Sebastiscus marmoratus* CUVIER et VALENCIENNES—I. On the monthly variation of gonad maturity. *Bull. Fac. Fish. Nagasaki Univ.*, **5**: 27—29. (In Japanese).
- 60) MIZUE, K. 1959. About the seasonal cycle of mature testis of *Sebastes inermis*. *Bull. Fac. Fish. Nagasaki Univ.*, **8**: 111—122. (In Japanese).
- 61) MIZUE, K. 1961. Studies on *Ditrema temmincki*-I. About the seasonal cycle of mature testis and the spermatogenesis. *Rec. Oceanogr. Works Special No. 5: 67—80.*
- 62) TESHIMA, K. and S. Koga. 1973. Studies on sharks. V. Taxonomic characteristics of reproductive organs in Japanese *Mustelus*. *Mar. Biol.*, **23**: 337—341.
- 63) MIZUE, K. 1959. Studies on a scorpaenous fish *Sebastiscus marmoratus* CUVIER et VALENCIENNES—IV. On the copulatory organ of the marine ovoviviparous teleost. *Bull. Fac. Fish. Nagasaki Univ.*, **8**: 80—83. (In Japanese).
- 64) ISHIYAMA, R. 1958. Studies on the rajid fishes (Rajidae) found in the waters around Japan. *J. Shimonoseki Coll. Fish.*, **7**: 193—394.
- 65) BOLAU, H. 1881. Über die Paarung und Fortpflanzung der Scyllium-Arten. *Z. Wiss. Zool.*, **35**: 321—325.
- 66) SCHENSKY, F. 1914. Tier- und Pflanzleben der Nordsee. *Werner Klinkhasdt. Leipzig*. (as cited by MATTHEWS, 1950).
- 67) HARDY, A. 1959. The open sea: its natural history. 322pp. William Brothers and Haram Ltd., London.
- 68) DEMPSTER, R.P. and E.S. HERALD. 1961. Note on the horn shark, *Heterodontus francisci*, with observation on mating activities. *Occ. Paper Calif. Acad. Sci.*, **33**: 1—7.
- 69) GOODEY, T. 1910. A contribution of the skeletal anatomy of the frilled shark, *Chlamydoselachus anguineus*. *Gar. Proc. Zool. Soc. London. Part I*. 540—571.
- 70) GILBERT, P.W. and G.W. HEATH.

1972. The clasper-siphon sac mechanism in *Squalus acanthias* and *Mustelus canis*. *Comp. Biochem. Physiol.*, **42**: 92—119.
- 71) LEIGH-SHARPE, W.H. 1921. The comparative morphology of the secondary sexual characters of elasmobranch fishes. Memoir II. *J. Morph.*, **35**: 359—380.
- 72) LEIGH-SHARPE, W.H. 1926. The comparative morphology of the secondary sexual characters of elasmobranch fishes. Memoir VIII, IX, X and XI. *J. Morph.*, **42**: 307—358.
- 73) LEIGH-SHARPE, W.H. 1920. The comparative morphology of the secondary sexual characters of elasmobranch fishes. Memoir. I. *J. Morph.*, **34**: 245—625.
- 74) LEIGH-SHARPE, W.H. 1920. The comparative morphology of the secondary sexual characters of elasmobranch fishes. Memoir III. *J. Morph.*, **36**: 191—198.
- 75) TANAKA, S., K. TESHIMA and K. MIZUE. 1975. Studies on sharks—X. Morphological and ecological study on the reproductive organs in male *Heptranchias perlo*. *Bull. Fac. Fish. Nagasaki Univ.*, **40**: 15—22.
- 76) GILBERT, P.W. 1943. The morphology of the male urogenital system of the frilled shark, *Chlamydoselachus anguineus*. *J. Morph.*, **73**: 507—528.
- 77) HEEMSTRA, P.C. 1972. Taxonomic study of the smooth dogfishes (*Mustelus* spp.) in the western Atlantic. Ph. D. Thesis. University of Miami.
- 78) MATSUBARA, K. 1936. Order Plagiostomi I. Fauna Nipponica. Vol. XV. Fasc. II. No. 1, 160pp. San Sei Do. Tokyo. (In Japanese).
- 79) MATSUBARA, K. 1955. Fish morphology and hierarchy I. 789pp. Ishizaki Shoten. Tokyo. (In Japanese).
- 80) BLEEKER, P. 1857. Ichthyologie van Japan. *Verh. Batav. Genootsch (Japan)*, **28**: 126—127.
- 81) PIETSCHMANN, V. 1908. Zwei neue japanische Haifische. *Anz. Akad. Wiss. Wien.*, **45**: 132—135.
- 82) TANAKA, S. 1916. Four new species of Japanese fishes. *Zool. Mag.*, **28**: 26—27. (In Japanese).
- 83) NAKAMURA, H. 1936. Reports of the investigation of the sharks of Taiwan. *Rep. Taiwan Fish. Exp. Stn.*, **7**: 1—54. (In Japanese).
- 84) SPRINGER, V.G. and J.A.F. GARRICK. 1964. A survey of vertebral numbers in sharks. *Proc. U.S. Natn. Mus.*, **116**: 73—96.
- 85) MAKIHATA, N. 1972. Reproduction in *Mustelus* spp. Unpublished Data.
- 86) TANAKA, S. 1911. Fishes of Japan. Vol. III. 16pp. Imperial University of Tokyo. Tokyo. (In Japanese).
- 87) SMITH, J.L.B. 1953. The sea fishes of Southern Africa, 564pp. Central news Agency Ltd. South Africa.
- 88) CHEN, J.T.F. 1963. A review of the sharks of Taiwan. *Biol. Bull. Tunghai Univ. (Ser. Ichthyol.)* **1**: 1—102.
- 89) DAY, F. 1870. Fishes of India. Vol. I. 788pp. London.
- 90) DAY, F. 1889. Fishes. Vol I. The fauna of British India including Ceylon and Burma. 584pp. Taylor and Francis. London.
- 91) STANLEY, H.P. 1971. Fine structure of spermatogenesis in the elasmobranch fish *Squalus suckleyi*. I. Acrosome formation, nuclear elongation and differentiation of the midpiece axia. *J. Ultrastruct. Res.*, **36**: 86—102.
- 92) STANLEY, H.P. 1971. Fine structure of spermatogenesis in the elasmobranch fish *Squalus suckleyi*. II. Late stage of differentiation and structure of the mature spermatozoon. *J. Ultrastruct. Res.*, **36**: 103—118.
- 93) SMITH, B.G. 1942. The heterodontid

- sharks: Their natural history, and the external development of *Heterodontus (Cestracion) japonicus* based on the notes and drawing by Bashford Dean. *Bashford Dean Mem. Vol. Archaic Fishes, Articles 8*: 647—784.
- 94) NAKAYA, K. 1975. Taxonomy, comparative anatomy and phylogeny of Japanese catsharks, Scyliorhinidae. *Memoi. Fac. Fish. Hokkaido Univ.*, 23:1—94.
- 95) KUDO, S. 1959. Studies on the sexual maturation of female and on the embryos of Japanese dogfish *Halaelurus buergeri* (MÜLLER et HENLE). *Rep. Nankai Reg. Fish. Res. Lab.*, 11: 41—46. (In Japanese).
- 96) SPRINGER, S. 1979. A revision of the catsharks, family Scyliorhinidae. NOAA Tech. Rep. NMFS Circ., 422: 1—52.
- 97) GUDGER, E.W. 1940. The breeding habits, reproductive organs and external embryonic development of *Chlamydoselachus*, based on the notes and drawing by Bashford Dean. *Bashford Dean Mem. Vol. Archaic Fishes, Articles 7*: 523—633.
- 98) CADENAT, J. 1959. Note d'ichnologie ouest-africaine XX. *Galeus polli* espece nouvelle ovovivipare de Scylliorhinidae. *Bull. Inst. Franc. d'Afri. Noire, Ser. A*, 1: 395—409.
- 99) AMOROSO, E.C. 1960. Viviparity in fishes. In *Hormones in fish*, 1: 153—181 Ed. by Jones, I.C., *Symp. Zool. Soc. London*.
- 100) COMPAGNO, L.J.V. 1970. Systematics of the genus *Hemitriakis* (Selachii: Carcharhinidae), and related genera. *Proc. Calif. Acad. Sci.*, 38: 63—98.
- 101) WOURMS, J.P. 1977. Reproduction and development in chondrichthyan fishes. *Amer. Zool.*, 17: 379—410.
- 102) TORTONESE, E. 1950. Studi sui Plagiostomi. III—La viviparita: Un fondamentale carattera biologico degli Squali. *Arch. Zool. Ital. Torino*, 35: 101—155.

日本産のホシザメとシロザメの生殖に関する研究

手島 和之

日本産のホシザメ属 *Mustelus* はホシザメ *M. manazo* BLEEKER とシロザメ *M. griseus* PIETSCHMANN の 2 種により構成される。ホシザメとシロザメの外部形態はともに良く似ているので、これらの 2 種のサメ類は分類の際に、しばしば、混同して使用された。しかしながら、これら 2 種の生殖器官や生殖様式を観察することにより、いくつかの違いが明らかとなった。特に、生殖様式は明瞭な違いを示した。すなわち、シロザメでは、妊娠の中期頃に、胎盤が形成されるが、ホシザメでは、胎盤は形成されない。