

Studies on Sharks— III.*

The Stage of Placentation and the Umbilical Stalk in *Carcharhinus dussumieri*

By

Kazuyuki TESHIMA

In the placental type selachians, the embryo in early developmental stage is nourished by yolk stored in the yolk sac. As the embryo grows, however, the distal surface of the yolk sac and the uterine wall are interdigitated each other to establish the yolk sac placenta. The embryo is, then, nourished by the placenta through the umbilical stalk until parturition. The yolk stalk is referred to as the umbilical stalk after establishment of the placenta.

It has been reported on *Scoliodon sorrakowah*¹⁾, *S. palasorrah*¹⁾, *Sphyrna tiburo*²⁾, *Carcharhinus falciformis*³⁾ and *C. dussumieri*⁴⁾ that the umbilical stalk contains 3 channels; umbilical artery, umbilical vein and ductus vitellointestinalis. These report, however, dealt only with the umbilical stalks, and had no mention of the yolk stalks.

The exchange of nutrition and blood seems to be different before and after establishment of the placenta. It is, hence, probable that structural differences between the yolk stalk and umbilical one are found in the 2 blood vessels and ductus vitellointestinalis. If these differences are found out, it may be possible to find the stage of placentation in the placental type selachians, and it seems to be important in respect to nutritional supply to the embryo to know this stage.

In the present study, investigation was carried out to clarify the stage of placentation through the histological observation on the cross section of the yolk stalks and umbilical ones of the embryos of *Carcharhinus dussumieri*.

The author wishes to express, here, hearty thanks to Prof. K. MIZUE of Nagasaki University for his invaluable advice and guidance in carrying out this work.

Materials and Methods

The yolk stalks and umbilical ones of the 7 embryos of *Carcharhinus dussumieri*

* Contribution from the Shimonoseki University of Fisheries, No. 689.
Received Dec. 25, 1972.

and 1 embryo of *C. sp.* were used in the present study. The total length of the embryos of *C. dussumieri* ranged from 27 to 266 mm and that of the embryo of *C. sp.* was 91 mm. These specimens were collected during trawling by the T. S. "Nagasaki Maru" of Nagasaki University in the waters off northwestern coast of Borneo in July of 1970. All were preserved in 10% formalin solution.

These materials were prepared by paraffin embedding, cut at 8–10 μ and stained with haematoxylin and eosin.

Observations

1. Ductus vitellointestinalis

The internal surface of the ductus vitellointestinalis, positioned between the 2 channels in the yolk stalk and umbilical one, consists of simple epithelium. That epithelium, however, shows no regularity in the change with embryonic development, e. g. the cuboidal epithelium in the embryo of 27 mm (Fig. 3), columnar one in the 80 mm embryo (Fig. 9) and both of the cuboidal and columnar cells in the embryo of 266 mm (Fig. 21). Reduction of the epithelium is also observed, e. g. in the embryos of 35, 40 and 266 mm (Figs. 5, 7 and 21).

The ciliated epithelium is developed in a part of the ductus vitellointestinalis of the embryo of over 80 mm in total length.

2. Blood vessels in the yolk stalk and umbilical one

Among the 3 channels in the yolk stalk and umbilical one, the 2 channels situated at both sides of the ductus vitellointestinalis are blood vessels.

When the embryos are 27–40 mm in total length, lumens and walls of the 2 blood vessels in the yolk stalks show the similar sizes (Figs. 2, 4 and 6).

When the embryo has attained more than 80 mm, differentiation, however, occurs between the 2 blood vessels; the lumen of one blood vessel becomes larger and its wall seems to be thinner than that of the other (Figs. 8, 12, 16 and 20). These differences are extremely obvious in the embryos of 177 and 266 mm in total length (Figs. 16 and 20). Moreover, in these 2 embryos, the walls of both of the blood vessels appear to consist of the 3 layers; tunica intima, tunica media and tunica adventitia, and the tunica media is composed of the 2, often indistinct, layers of smooth muscle.

These facts indicate that the 2 blood vessels in the stalk of the embryo of over 80 mm in total length are differentiated into an artery and a vein; the small blood vessel with thicker muscle layer develops into an umbilical artery and the other into an umbilical vein.

Development of some other small blood vessels is also observed in the sheath tissue of stalk of the embryo more than 80 mm.

3. The stage of placentation

In selachians, the placenta consists of a maternal placental and a foetal placental

portion^{1),2),3),4)}. The stage when these 2 portions are interdigitated is considered to be the stage of placentation.

The supplying system of nutrition and blood in the yolk stalk and umbilical one seems to be different before and after establishment of the placenta. The following 2 characters are, therefore, considered to be applicable to appraising the stage of placentation; 1) epithelium of the ductus vitellointestinalis and 2) blood vessels in the stalk.

As described previously, the epithelium of the ductus vitellointestinalis shows no regularity in change in accordance with development of the embryo, and this character seems to be unsuitable for the present purpose.

After establishment of the placenta, the exchange of blood and nutrition between the embryo and the maternal tissue should be done through the placenta, and it is considered that the 2 blood vessels in the stalk function as the umbilical artery and the umbilical vein. The differentiation of the blood vessels, therefore, seems to be one of the characters suitable for estimating the stage of placentation.

The 2 blood vessels in the stalk of the embryo of over 80 mm are already differentiated into an artery and a vein as described previously. Moreover, some other small blood vessels are also observed in the stalk sheath. These findings indicate that the yolk sac has interdigitated with the uterine wall. Hence, in *Carcharhinus dussumieri*, the placenta is established when the embryo has attained the total length of about 80 mm.

4. Comparison of the umbilical stalk of other species

Regarding the umbilical stalk, selachians are divided into two groups; one group develops special structures called the appendiculae⁵⁾ on the sheath of umbilical stalk, and the second forms no appendiculae and that umbilical stalk shows the smooth surface. Appendiculae are present, e. g. in *Scoliodon sorrakowah*¹⁾, *S. palasorrah*¹⁾, *S. walbeehmi*¹⁾, *Sphyrna tiburo*²⁾ and *Carcharhinus sp.*⁴⁾ (Fig. 24), and absent, e. g. in *C. falciformis*³⁾ and *C. dussumieri*⁴⁾, a material of the present study.

The appendiculae formed by modification of the sheath of the umbilical stalk are extensions of extra-embryonic somatopleure, and they become longer, thicker and more vascular as the embryo grows. Some types of appendiculae have been known in accord with their forms, and the appendiculae of the above-mentioned species show the different forms. In *Carcharhinus sp.*, appendiculae extend stellately and a few are found to be forked (Figs. 24 and 25). The outer rinds of appendiculae are lined by columnar cells. These cells appear to have the amoeboid borders as described in *Scoliodon sorrakowah* and *S. palasorrah* by MAHADEVAN¹⁾, and they are considered to possess phagocytosis and pinocytosis. The large vessel located near the center of appendicula (Fig. 29) appears to be a blood vessel as found in *S. sorrakowah* and *S. palasorrah*, and some capillaries are also developed beneath the basement membrane of the epithelium of appendicula. The function of these appendiculae appears to be absorption of the uterine secretions^{1),2),5)}.

The external epithelium of the stalk sheath in *Carcharhiuns dussumieri* appears to consist of two or three layers of cells; external surface is lined by a layer of cuboidal (110 mm embryo) or short columnar (177 and 266 mm embryos) cells, and the next is

one or two layers of squamous cells, though a trilaminar squamous epithelium in *C. falciformis*³⁾. Internal to these layers is loose connective tissue in which small blood vessels and capillaries are developed, and the sheath is bounded internally by the mesothelium.

The fusion of the mesodermal portions of the splanchnopleure and the somatopleure, especially at the portion of the umbilical artery, occurs as described in *Sphyrna tiburo*²⁾.

Although the above comparisons are concerned with the umbilical stalks, a few specimens of the yolk stalks in the non-placental species on the author's hand appear to show the different structures. These will be described elsewhere.

Discussion

The author, in the previous paper⁴⁾, described that the placenta of *Carcharhinus dussumieri* is established when the embryo is about 150 mm in total length through the gross observation. In the present investigation, however, histological observation shows that the placenta of this species is established when the embryo has attained about 80 mm.

In a well-developed placenta, whether the placenta is established or not is easily distinguished by the gross observation, because a maternal placental tissue is tightly interdigitated with a foetal one. At the stage just posterior to establishment, however, the foetal is easily exfoliated from the maternal tissue. This made it hard to appraise the exact stage of placentation. This misled the author to a conclusion that the placenta of this species is established when the embryo is about 150 mm, i. e. when the yolk is completely consumed.

The placenta is already established when the embryo has attained 80 mm. At this stage, however, the muscle layers in the blood vessels are not so clear as that shown in the embryos of 177 and 266 mm (Figs. 18, 19, 22 and 23). Namely, it is considered that the 2 blood vessels are not well developed yet into an umbilical artery and an umbilical vein. This suggests that this stage should be just posterior to establishment of the placenta.

Although the placenta is established when the embryo has attained the total length of 80 mm, yolk in the yolk sac remains till the embryo is about 150 mm as described in the previous paper⁴⁾. The embryo may be, therefore, nourished by both of yolk and placenta during the developmental stage from 80 mm to 150 mm, and the placenta seems to be developing in this stage.

It is considered that the embryonic stage of *Carcharhinus dussumieri* may be divided into the following 3 stages according to nutritional supply system; 1) the stage nourished mainly by yolk stored in the yolk sac (to about 80 mm), 2) that nourished by the yolk and placenta (about 80 to 150 mm); this stage is also in the developmental stage of the placenta, 3) that nourished mainly through a well-developed placenta (about 150 mm to parturition); umbilical artery and umbilical vein are well developed.

SCHLERNITZAUER and GILBERT²⁾ have described, in *Sphyrna tiburo*, that there is apparently

a period of three to four weeks between the commencement of interdigitation and the establishment of a well-developed placenta. This period would appear to apply to the developmental stage of the placenta of *Carcharhinus dussumieri*.

The external gill filaments of *Carcharhinus dussumieri* are formed when the embryo is about 25 mm in total length, and they become longer as the embryo grows. The embryo of 100 mm possesses the external gill filaments of 9–10 mm long, but they disappear when the embryo is about 150 mm. These external gill filaments are also considered to absorb the uterine secretions in early developmental stage of the embryo.

MAHADEVAN¹⁾ has described that species with the best developed appendiculae forms the best developed placenta. As described previously, however, there are species with or without appendiculae in the placental type selachians, and the placental species includes two types; simple pregnancy and multiple pregnancy. Simple pregnancy appears to be much more evolved than multiple pregnancy. *C. dussumieri* (not by MAHADEVAN) of the present study belongs to the simple pregnancy type, and this species forms no appendiculae. The formation of appendiculae would not, therefore, appear to be a character suitable for the present problem.

Summary

1. When the embryo is small (27–40 mm), the 2 blood vessels in the yolk stalk are not yet differentiated; when the embryo attains more than 80 mm, the lumen of one blood vessel becomes larger, and its wall seems to be thinner than that of the other. Also some other small blood vessels are formed in the sheath tissue of the stalk.

2. Of the 2 blood vessels in the stalk, the small one with thicker muscle layer develops into an umbilical artery and the other into an umbilical vein.

3. It may be possible, therefore, to find the stage of placentation through the histological observation on the blood vessels in the stalk.

4. It was clarified that the placenta of *Carcharhinus dussumieri* is established when the embryo is about 80 mm in total length.

5. The embryonic stage of this species may be divided into the following 3 stages according to nutritional supply system;

1) The stage nourished mainly by yolk stored in the yolk sac (to about 80 mm in total length),

2) That nourished by the yolk and through the placenta (about 80 to 150 mm); this is also developmental stage of the placenta,

3) That nourished mainly through the well-developed placenta (about 150 mm to parturition).

References

- 1) MAHADEVAN, G., 1940: Preliminary observation on the structure of uterus and the placenta of a few Indian elasmobranchs. *Proc. Indian Acad. Sci. (Sect. B)*, **11**, 2-40.
- 2) SCHLERNITZAUER, D. A. and P. W. GILBERT, 1966: Placentation and associated aspects of gestation in the bonnethead shark *Sphyrna tiburo*. *J. Morph.*, **120** (3), 219-231.
- 3) GILBERT, P. W. and D. A. SCHLERNITZAUER, 1966: The placenta and gravid uterus of *Carcharhinus falciformis*. *Copeia* **1966** (3), 451-457.
- 4) TESHIMA, K. and K. MIZUE, 1972: Studies on Sharks. I. Reproduction in the female sumitsuki shark *Carcharhinus dussumieri*. *Mar. Biol.*, **14** (3), 222-231.
- 5) ALCOCK, A., 1890: Observations on the gestation of some sharks and rays. *J. Asiat. Soc. Bengal*, **59** (2), 51-56.

PLATE

Explanation of Figures

a ----	appendicula,	m ----	mesothelium,
bv ---	blood vessel,	s -----	sheath,
c ----	capillary,	sm ---	smooth muscle layer,
ce ---	ciliated epithelium,	ua ----	umbilical artery,
d ----	ductus vitellointestinalis,	uv ---	umbilical vein
e ----	extra-embryonic coelom ,		

PLATE I

- Fig. 1. An embryo (266 mm in total length) of *Carcharhinus dussumieri* and the umbilical stalk. The foetal placental portion is contained in the maternal placental pocket (pocket type placenta).
- Fig. 2. Transverse section of yolk stalk (embryo : 27 mm), 6.7×4 . The 2 blood vessels in the stalk show the similar sizes.
- Fig. 3. The enlarged photograph of Fig. 2 showing ductus vitellointestinalis, 6.7×40 .
- Fig. 4. Transverse section of yolk stalk (embryo : 35 mm), 6.7×4 . The 2 blood vessels in the stalk show the similar sizes.
- Fig. 5. The enlarged photograph of Fig. 4 showing ductus vitellointestinalis, 6.7×40 .
- Fig. 6. Transverse section of yolk stalk (embryo : 40 mm), 5×4 . The 2 blood vessels in the stalk show the similar sizes.
- Fig. 7. The enlarged photograph of Fig. 6 showing ductus vitellointestinalis, 5×40 .

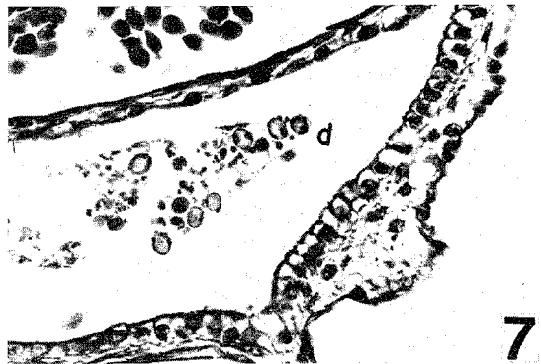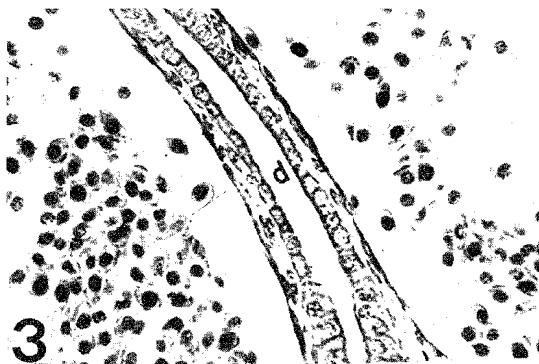
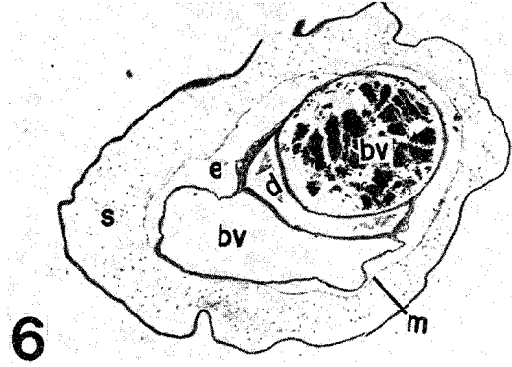
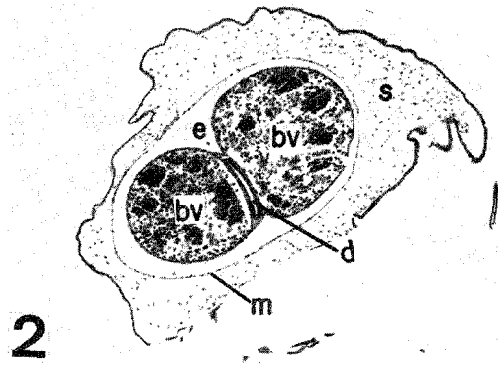
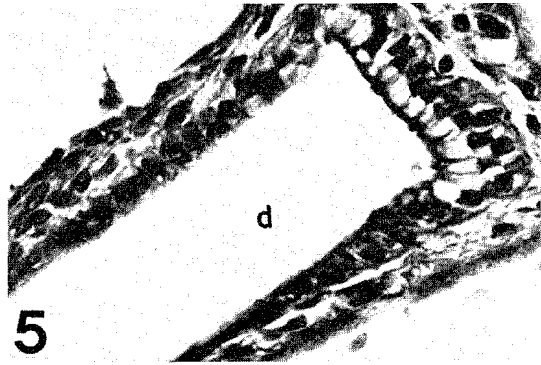
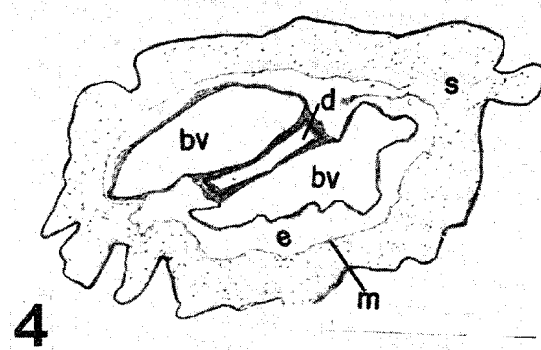

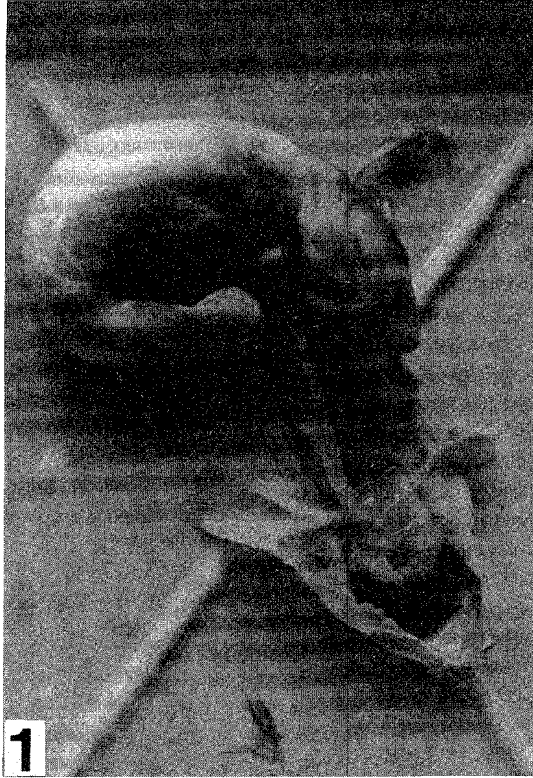
PLATE II

- Fig. 8. Transverse section of umbilical stalk(embryo:80mm), 5×4 . The 2 blood vessels in the stalk seems to be differentiated into an artery and a vein, and some other small blood vessels are developed in the stalk sheath.
- Fig. 9. The enlarged photograph of Fig.8 showing ductus vitellointestinalis, 5×40 . The short ciliated columnar epithelium covers the ductus vitellointestinalis.
- Fig. 10. The enlarged photograph of Fig. 8 showing the wall of umbilical artery, 5×40 .
- Fig. 11. The enlarged photograph of Fig. 8 showing the wall of umbilical vein, 5×40 . The wall of the umbilical artery seems to be thicker than that of the umbilical vein.
- Fig. 12. Transverse section of umbilical stalk (embryo : 110 mm), 5×2 .
- Fig. 13. The enlarged photograph of Fig. 12 showing ductus vitellointestinalis, 5×40 .
- Fig. 14. The enlarged photograph of Fig. 12 showing the wall of umbilical artery, 5×40 .
- Fig. 15. The enlarged photograph of Fig. 12 showing the wall of,umbilical vein, 5×40 .

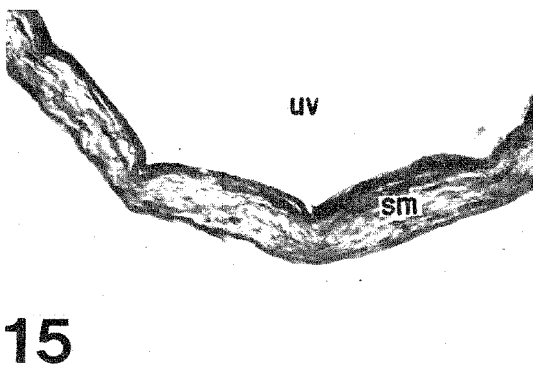
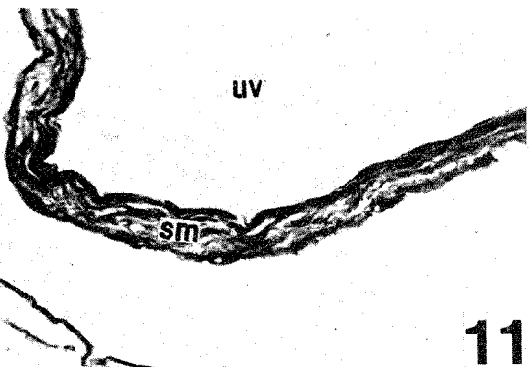
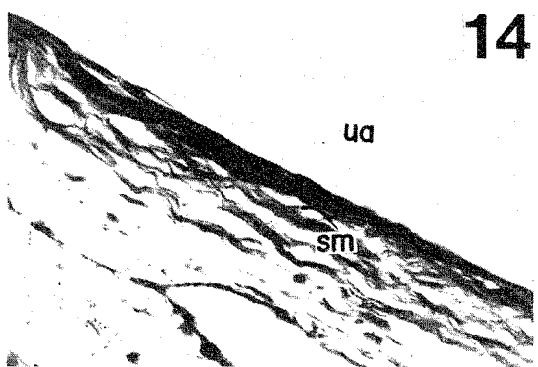

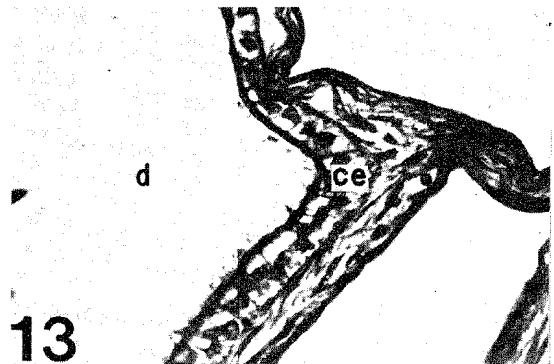
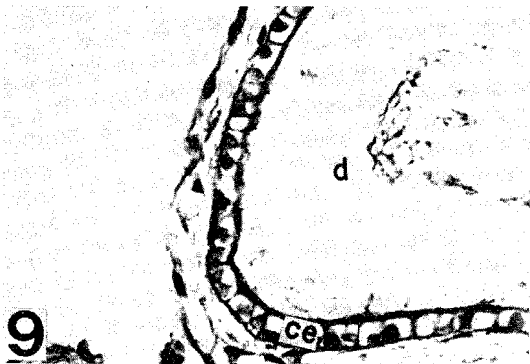
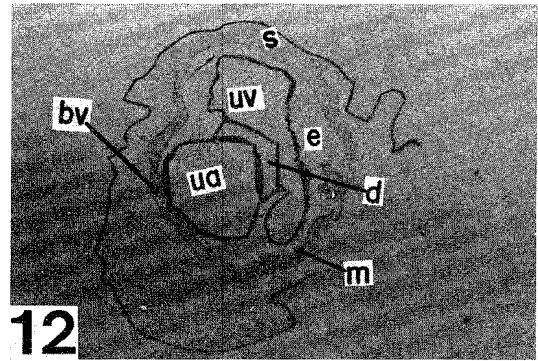
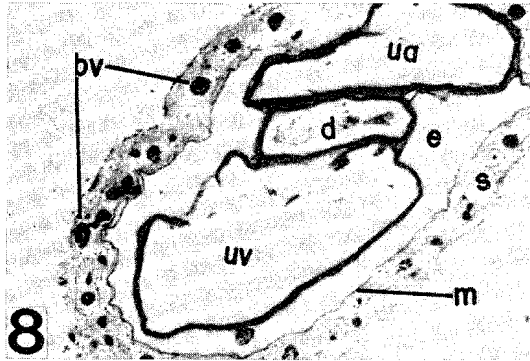


PLATE III

- Fig. 16. Transverse section of umbilical stalk (embryo : 177 mm), 5×2 . The 2 blood vessels in the stalk are well developed into the umbilical artery and the umbilical vein; at this stage, placenta well developed.
- Fig. 17. The enlarged photograph of Fig.16 showing ductus vitellointestinalis, 5×10 .
- Fig. 18. The enlarged photograph of Fig. 16 showing the wall of umbilical artery, 5×40 . The wall consists of the 3 layers, and the tunica media is composed of the 2 layers of smooth muscle.
- Fig. 19. The enlarged photograph of Fig. 16 showing the wall of umbilical vein, 5×40 . The wall consists of the 3 layers.
- Fig. 20. Transverse section of umbilical stalk (embryo : 266 mm), 5×2 . At this stage, placenta well established.
- Fig. 21. The enlarged photograph of Fig. 20 showing ductus vitellointestinalis, 5×40 . Reduction of the epithelium is observed.
- Fig. 22. The enlarged photograph of Fig. 20 showing the wall of umbilical artery, 5×40 . The tunica media consists of the 2 layers of smooth muscle.
- Fig. 23. The enlarged photograph of Fig. 20 showing the wall of umbilical vein, 5×40 . The wall consists of the 3 layers.

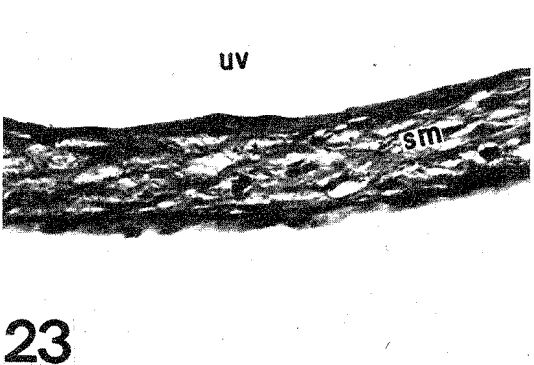
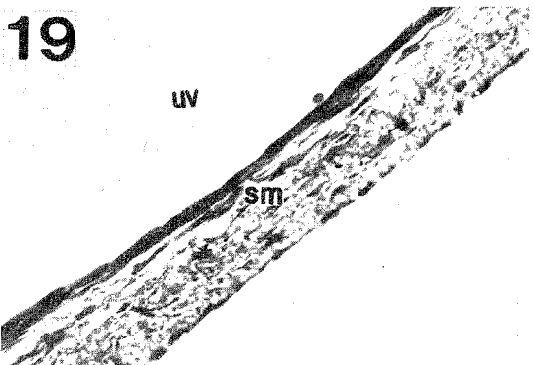
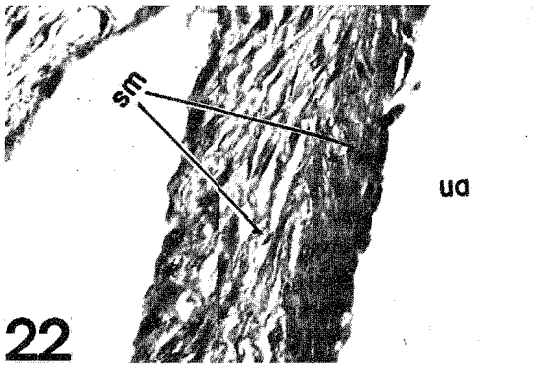
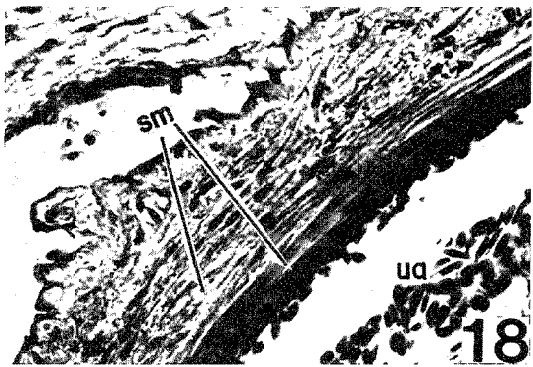
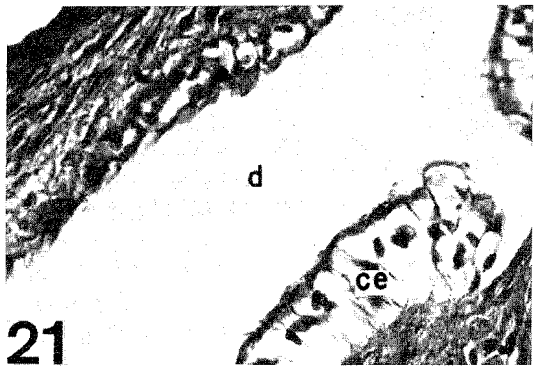
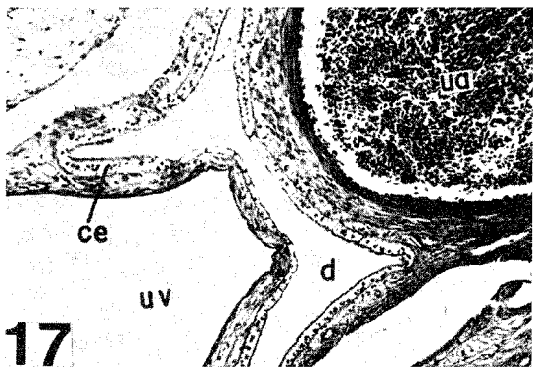
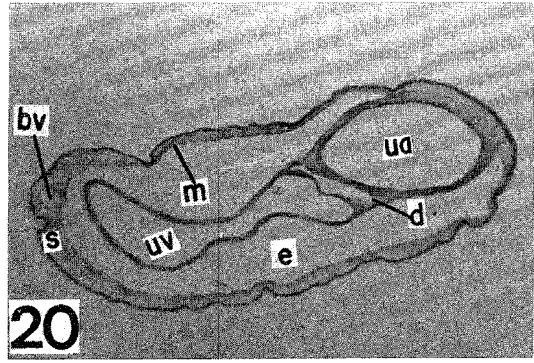
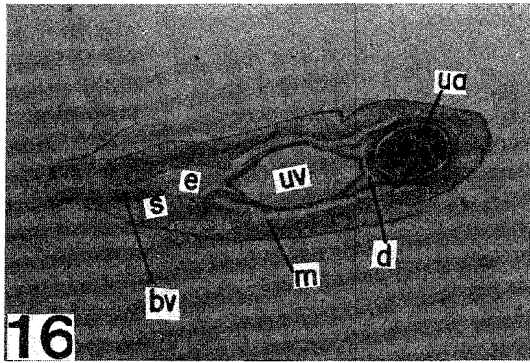


PLATE IV

- Fig. 24. The embryos of *Carcharhinus* sp. showing appendiculae on the umbilical stalks.
- Fig. 25. Transverse section of umbilical stalk of *Carcharhinus* sp. (embryo : 91 mm in total length), 5 x 4. The appendiculae extend stellately.
- Fig. 26. The enlarged photograph of Fig. 25 showing ductus vitellointestinalis, 5 × 40. The ciliated columnar epithelium is well developed.
- Fig. 27. The enlarged photograph of Fig. 25 showing the wall of umbilical artery, 5 × 40.
- Fig. 28. The enlarged photograph of Fig. 25 showing the wall of umbilical vein, 5 × 40.
- Fig. 29. The enlarged photograph of Fig. 25 showing an appendicula, 5 × 40. A large blood vessel is located near the center of that appendicula and some capillaries are observed.

